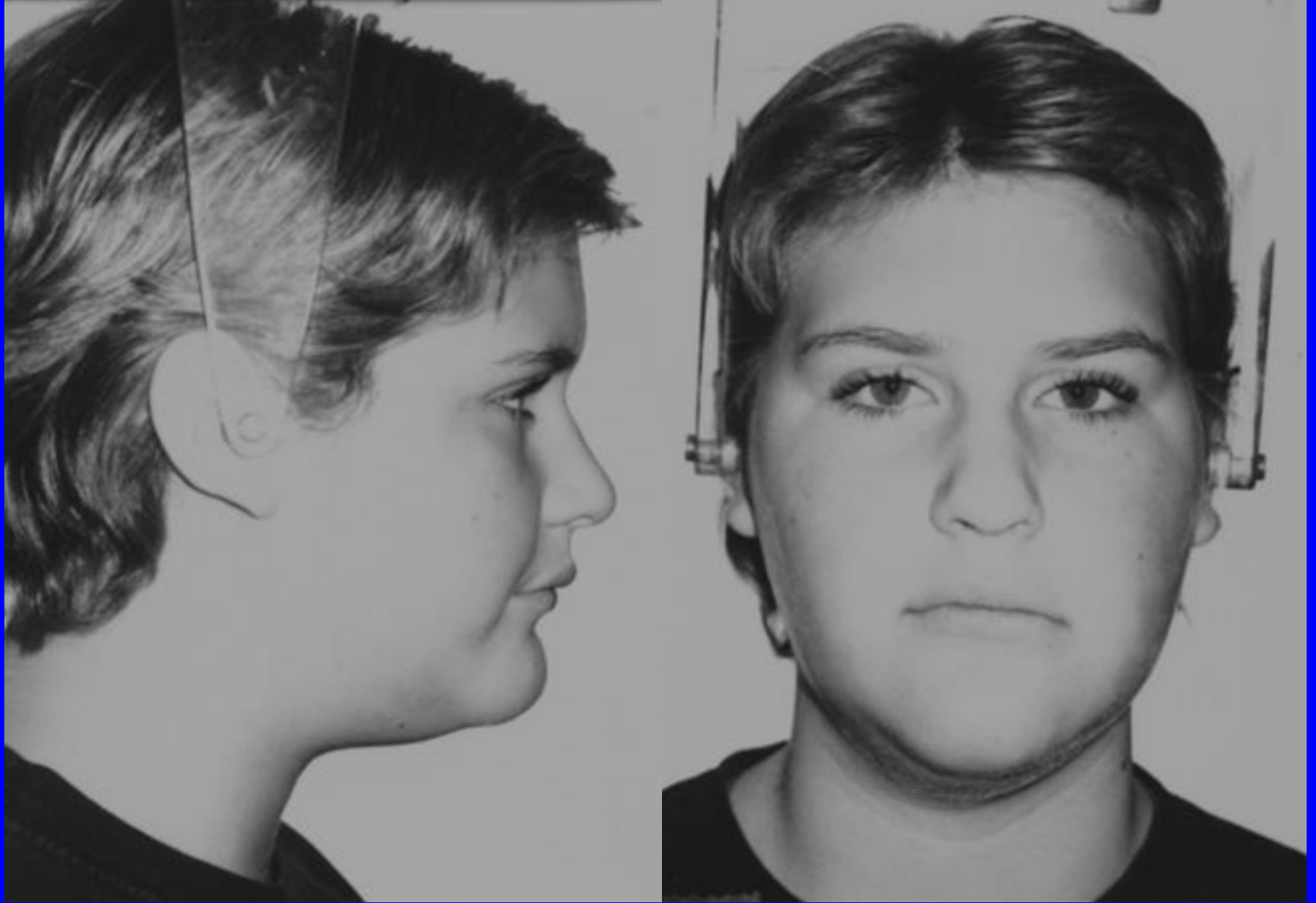

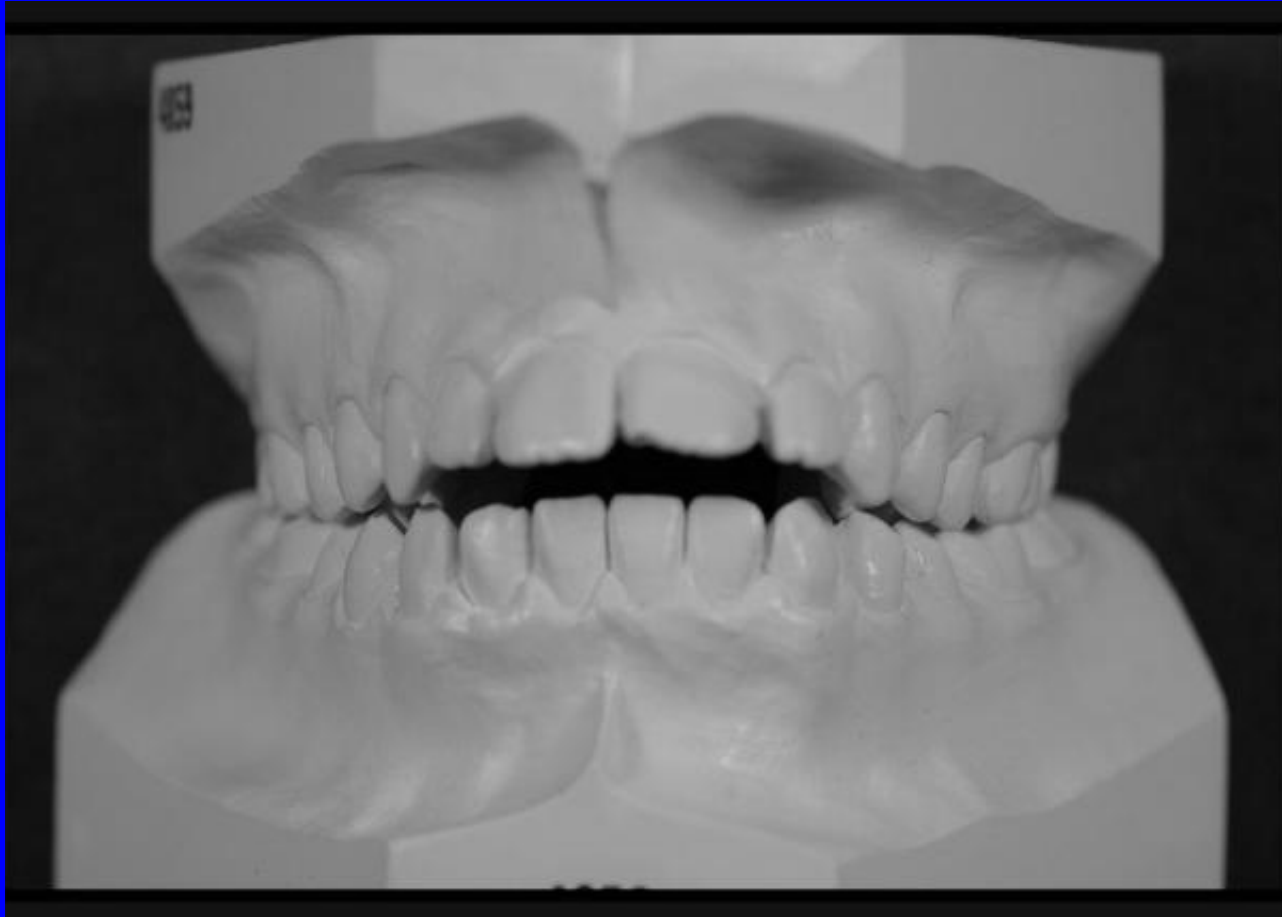M. BAXTER

PRETREATMENT RECORDS

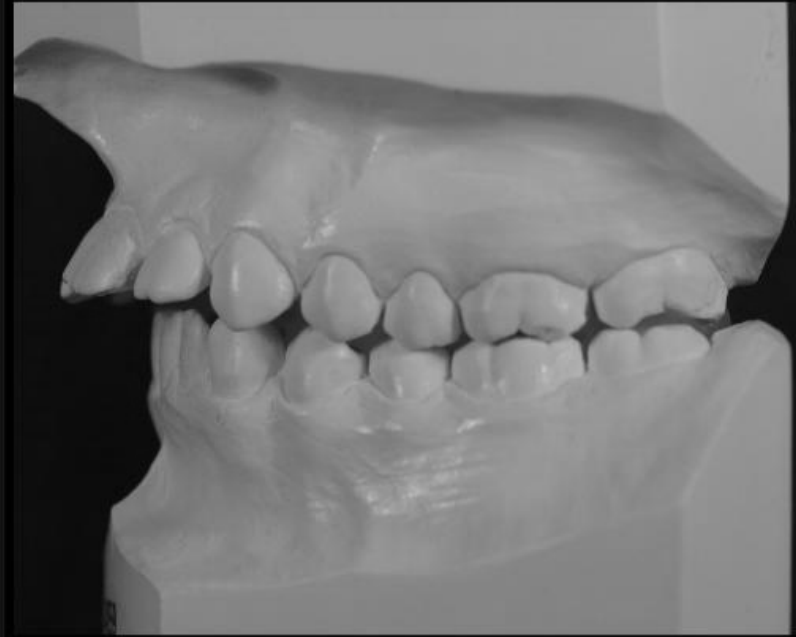
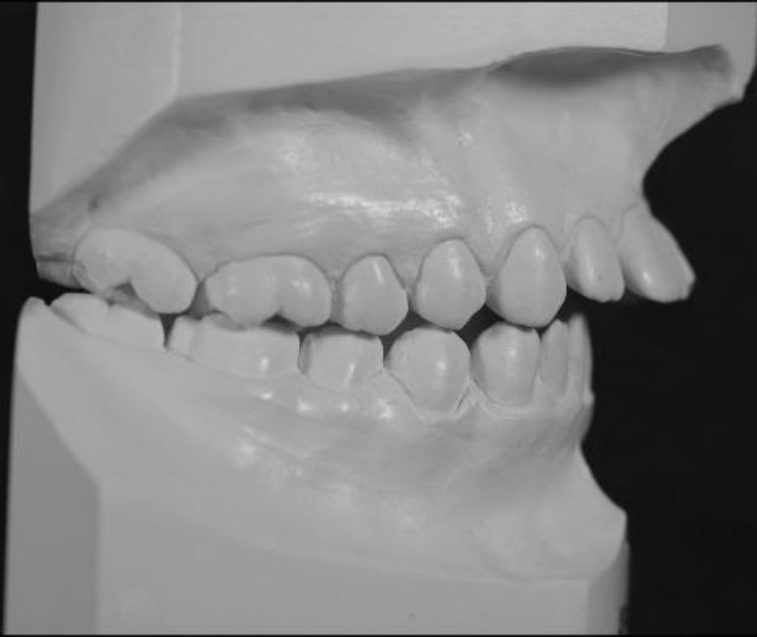
This thirteen year old female patient has “reasonable” facial esthetics, but a significant Class II occlusion and an anterior open bite. A tongue habit contributed to the malocclusion.



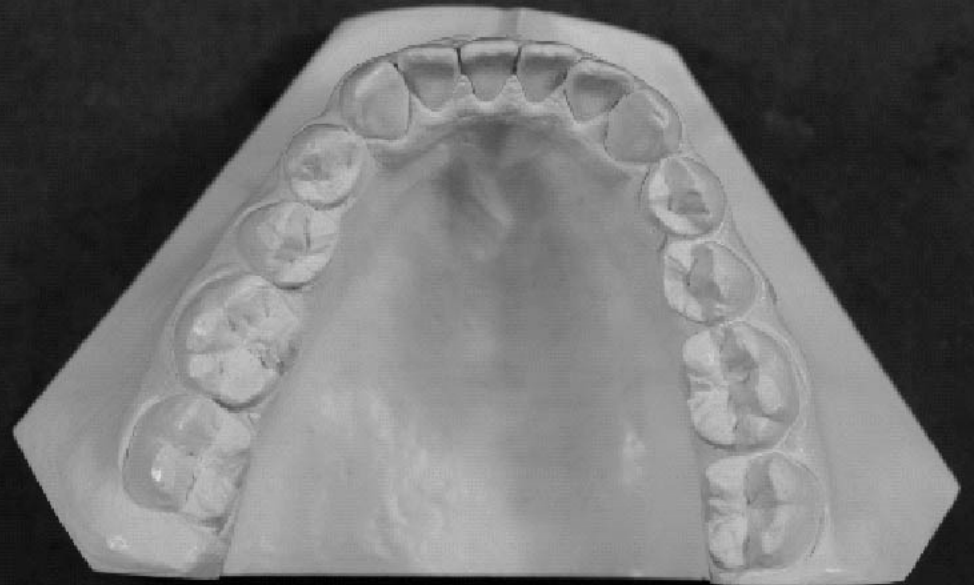
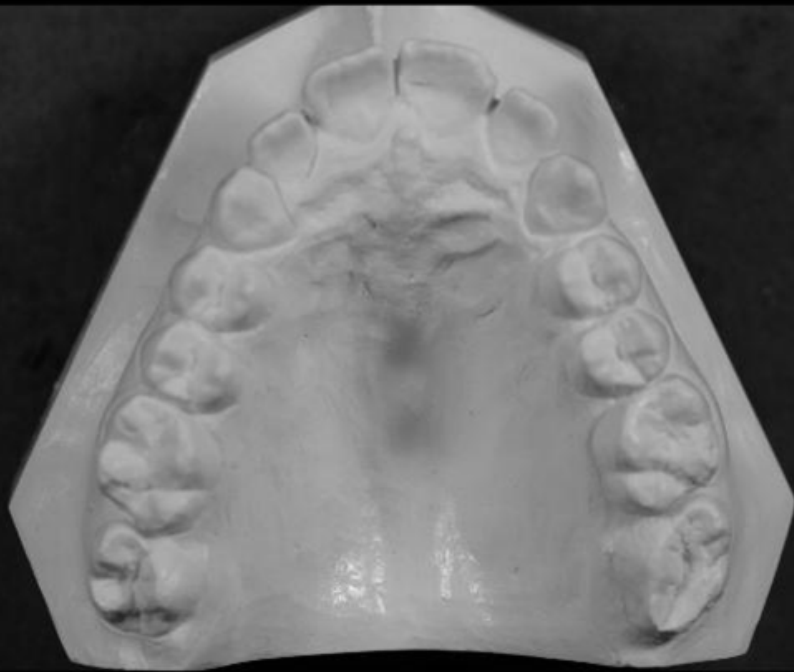M. Baxter



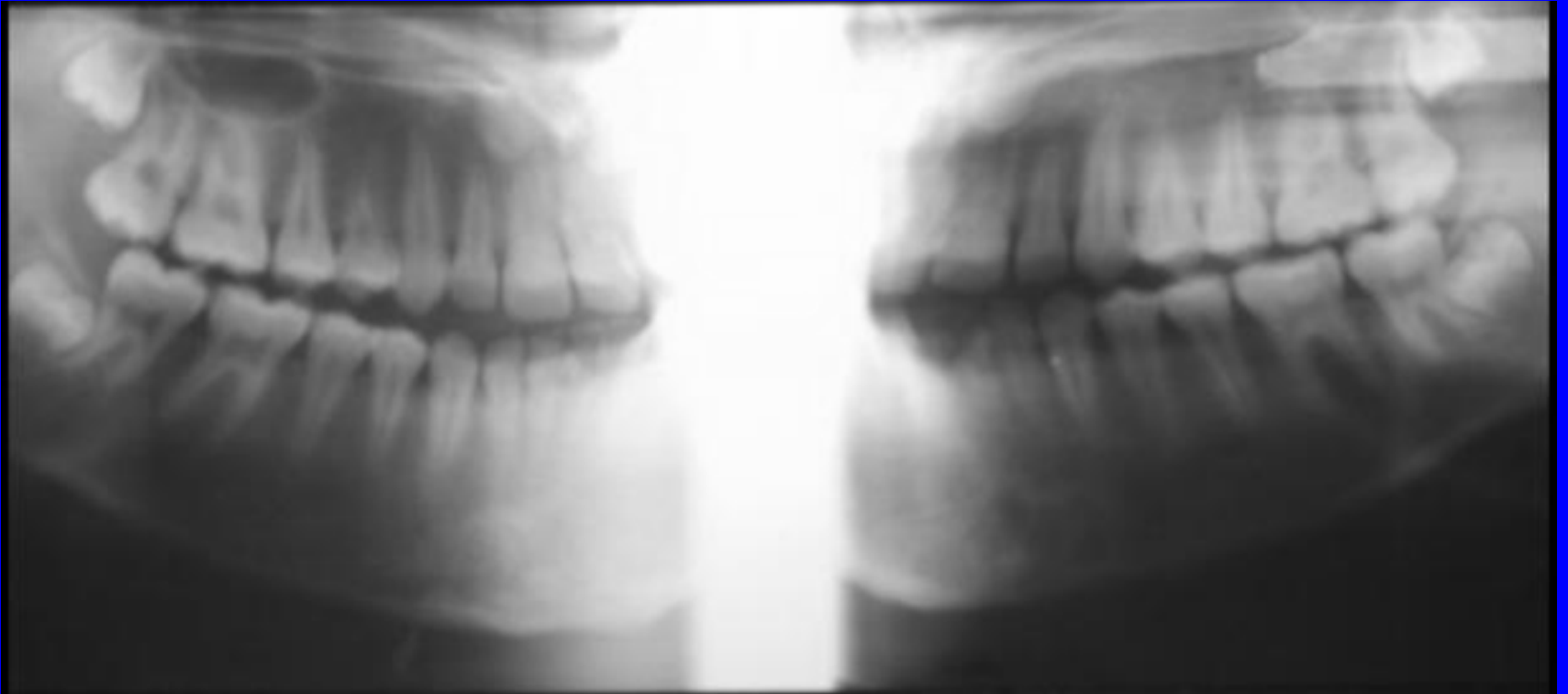
M. Baxter



M. Baxter

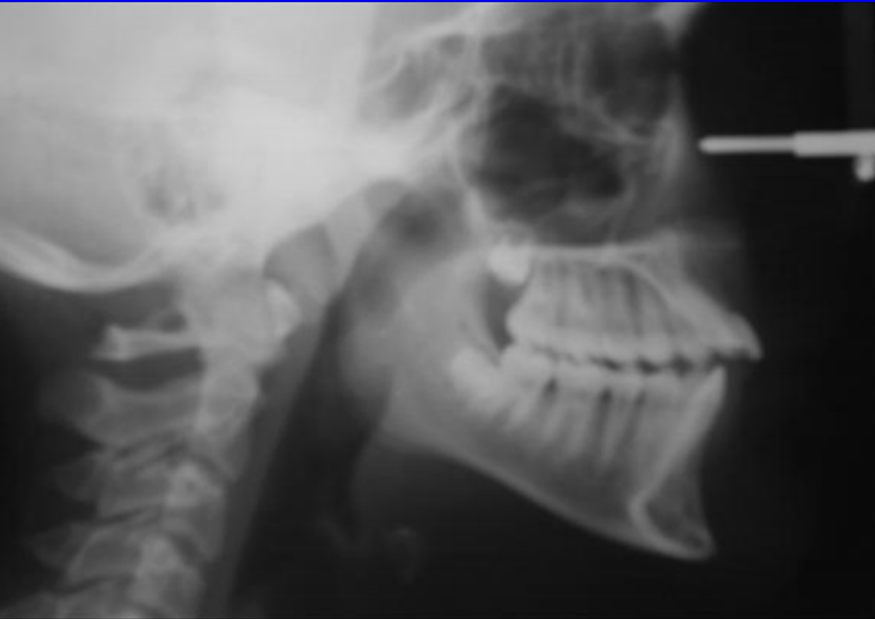


M. Baxter



M. Baxter

M. Baxter Pretreatment



FMIA 66

FMA 24

IMPA 90

SNA 80

SNB 76

ANB 4

AO BO 3mm

OCC 2

Z 82

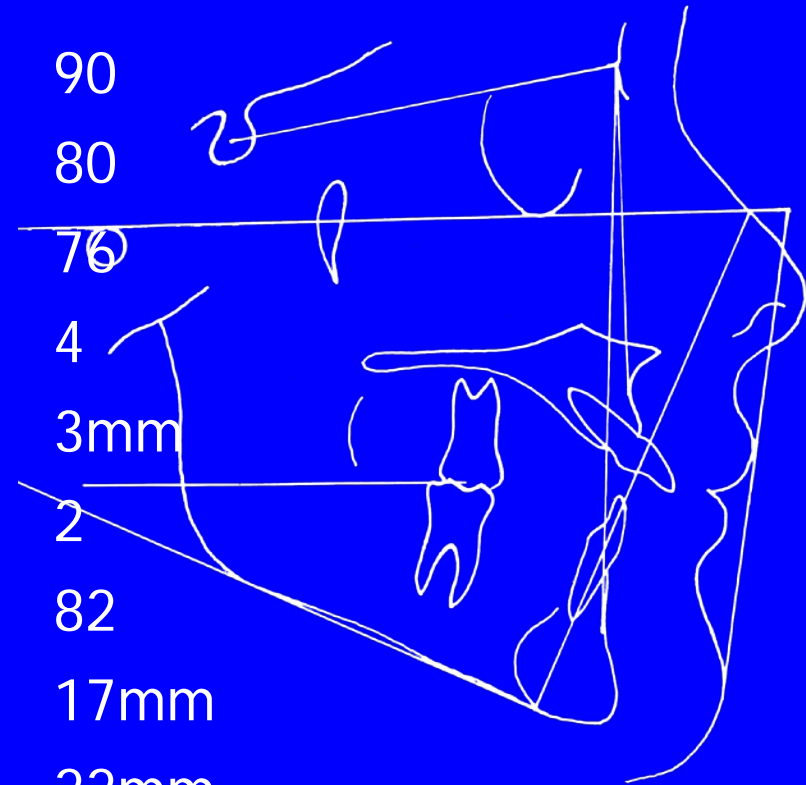
UL 17mm

TC 22mm

PFH 45mm

AFH 66mm

INDEX .68



M. Baxter

CRANIAL FACIAL ANALYSIS

	CEPH.	DIFFICULTY	
NORMAL RANGE	VALUE	FACTOR	DIFF
FMA 22°- 28°	24	5	0
ANB 1°- 5°	4	15	0
Z ANGLE 70°- 80°	82	2	4
OCC PLANE 8°-12°	2	3	18
SNB 78°-82°	76	5	10
PFH-AFH .65-.75	.68	3	3
M. Baxter			
		C.F. DIFFICULTY TOTAL	35

TOTAL SPACE ANALYSIS

		WEIGHTED	
		VALUE	DIFF
ANTERIOR			
TOOTH ARCH DISC.	0	1.5	0
HEADFILM DISC.	0	1	0
TOTAL	0		0
MID ARCH			
TOOTH ARCH DISC.	0		
CURVE OF SPEE	2		
TOTAL	2	1	2
OCCLUSAL DISHARMONY			
(CLASS II OR CLASS III)	6	2	12

M. Baxter

TOTAL SPACE ANALYSIS

		DIFFICULTY FACTOR	DIFF
POSTERIOR			
TOOTH ARCH DISC.	16		
(-) EXPECTED INC.	0		
TOTAL	16	.5	8
	TOTAL S.A.		S.A. DIFF
ANTERIOR	0		0
MID ARCH	2		2
POSTERIOR	16		8
TOTAL	18		10

M. Baxter

C.F. DIFFICULTY	35
S.A. DIFFICULTY	10
TOTAL DIFFICULTY	45

M. Baxter

DIFFERENTIAL DIAGNOSIS AND CLINICAL ANALYSIS

INDEX DIFFICULTY:

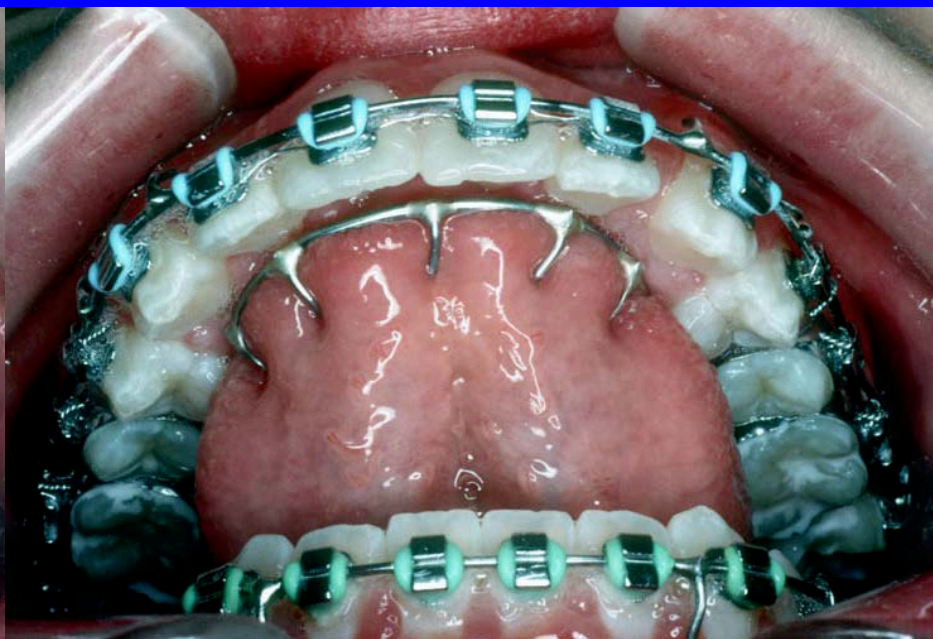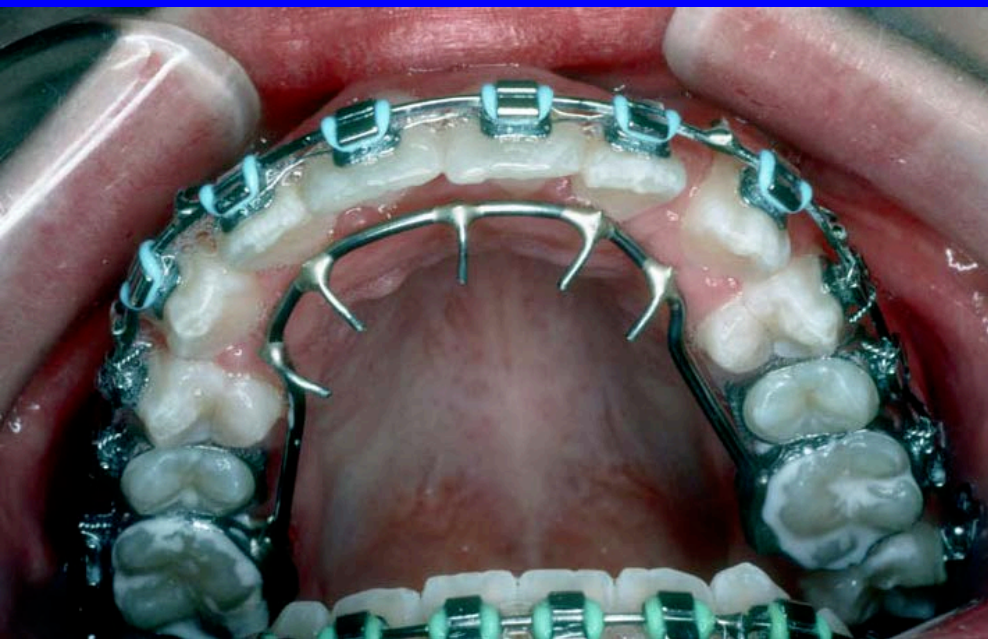MILD 0-60

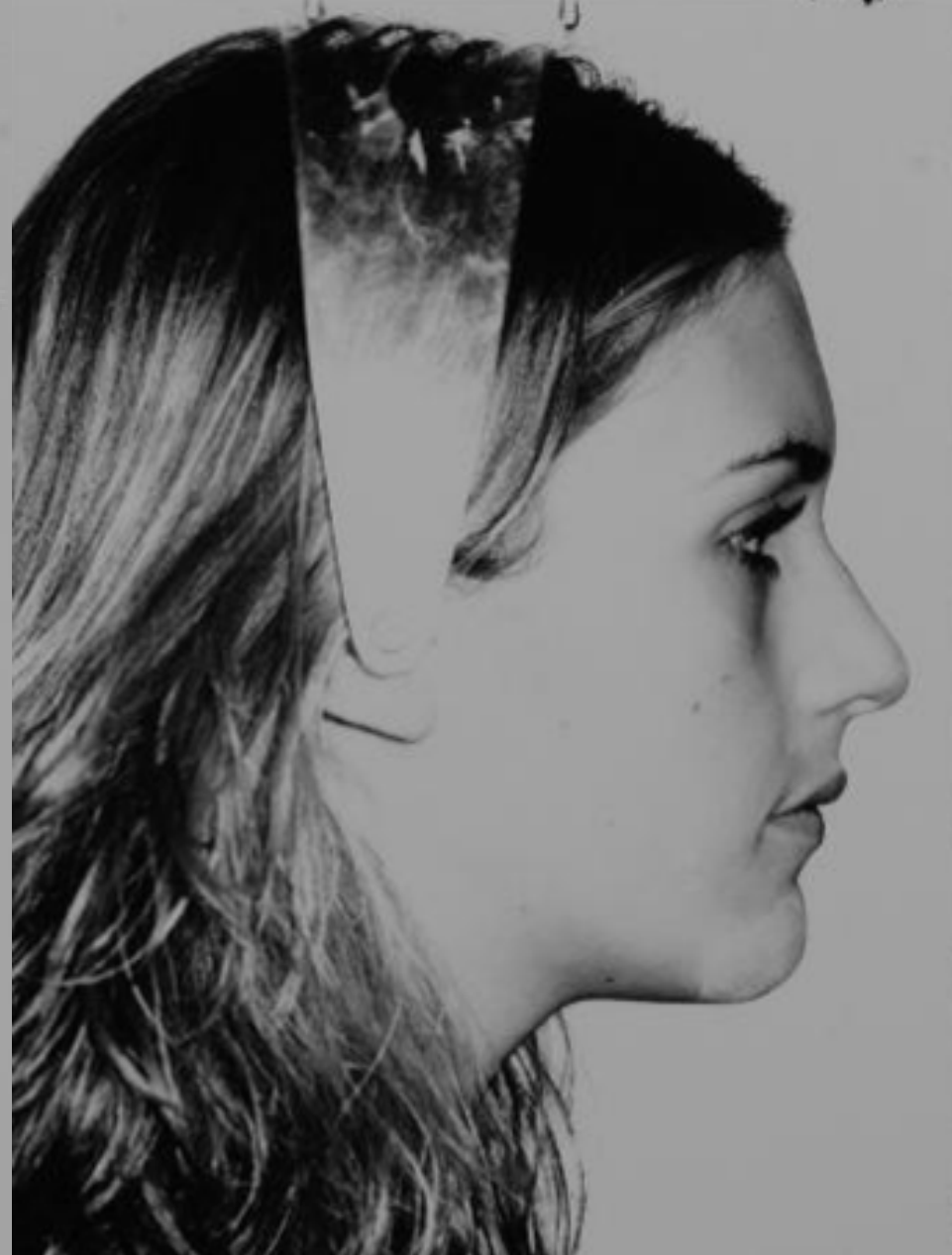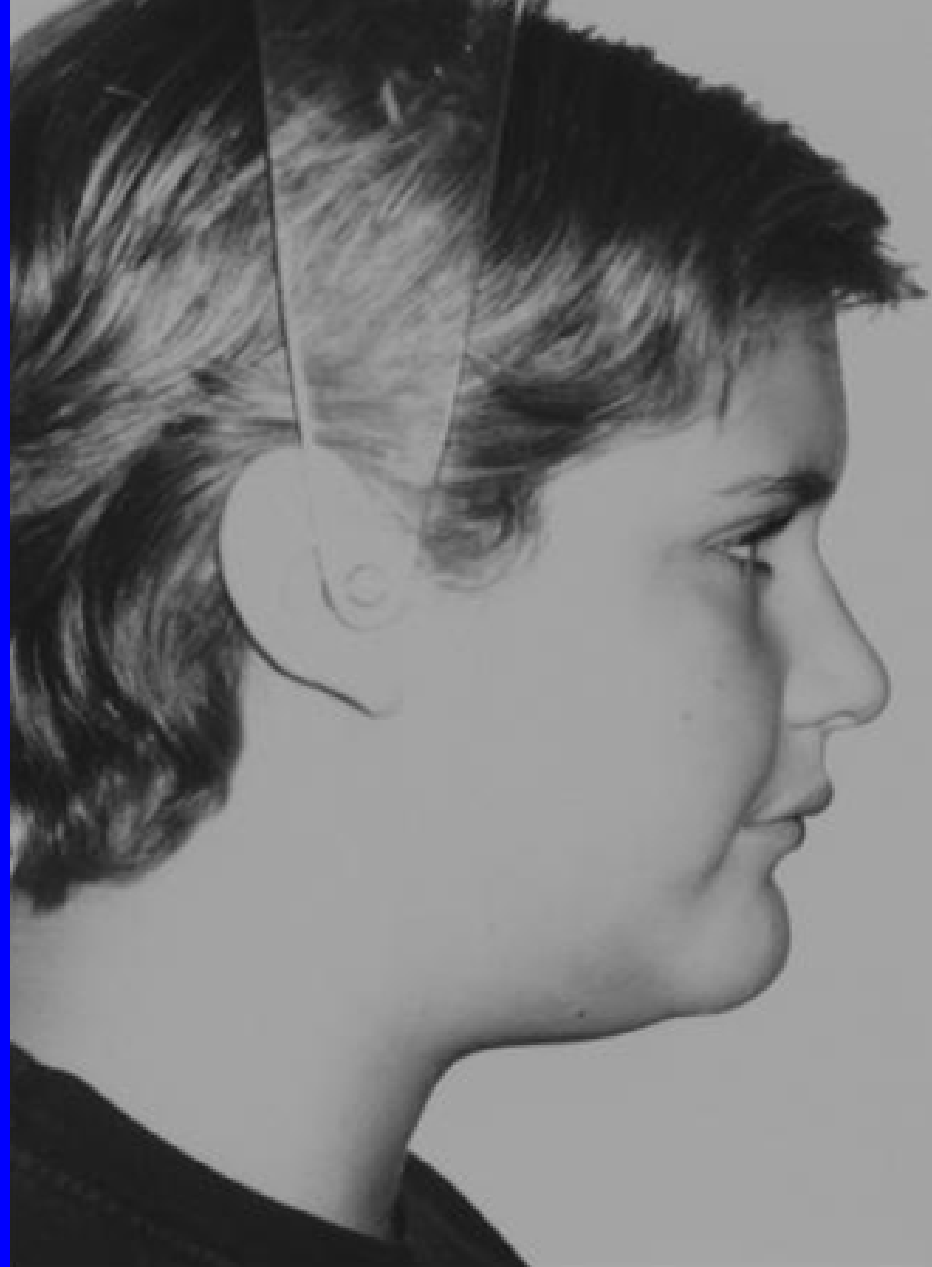MODERATE 60-120

SEVERE 120+

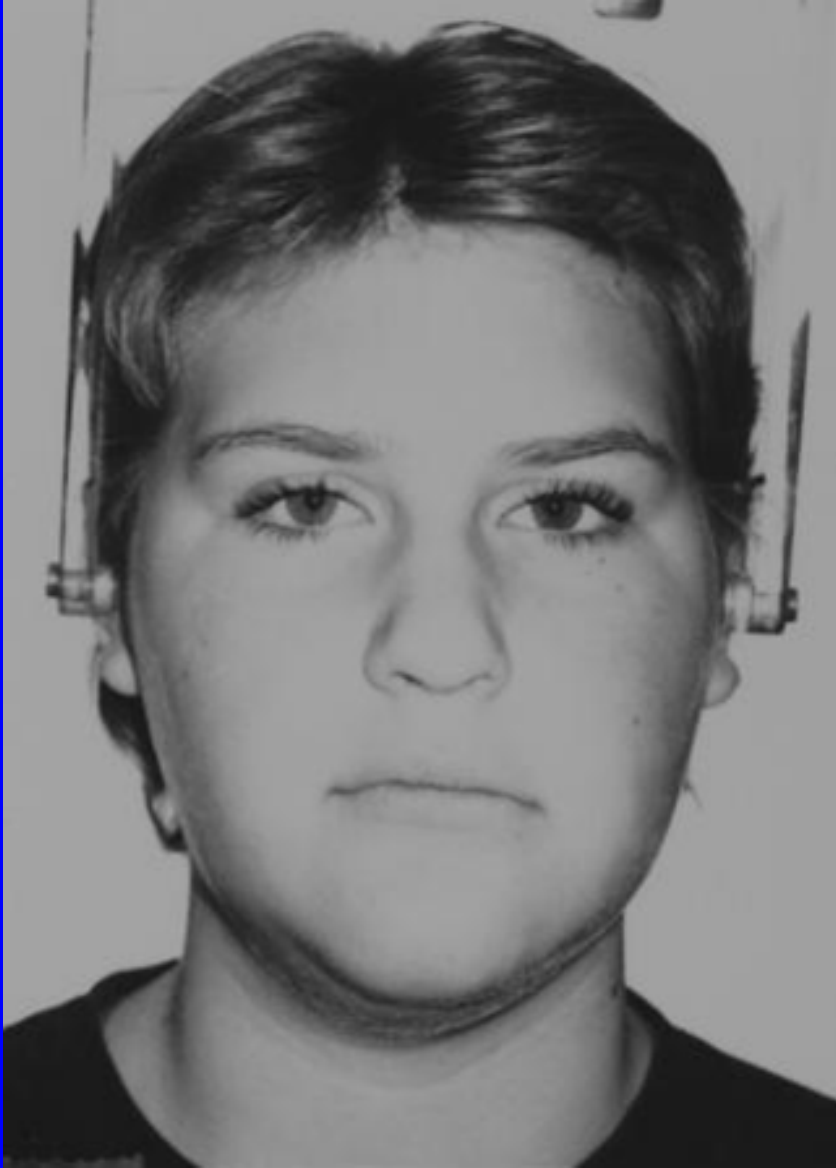TREATMENT PLAN:

1. Extract maxillary and mandibular third molars.
2. Prepare the mandibular arch.
3. “Distalize” the maxillary arch.
4. Control the tongue

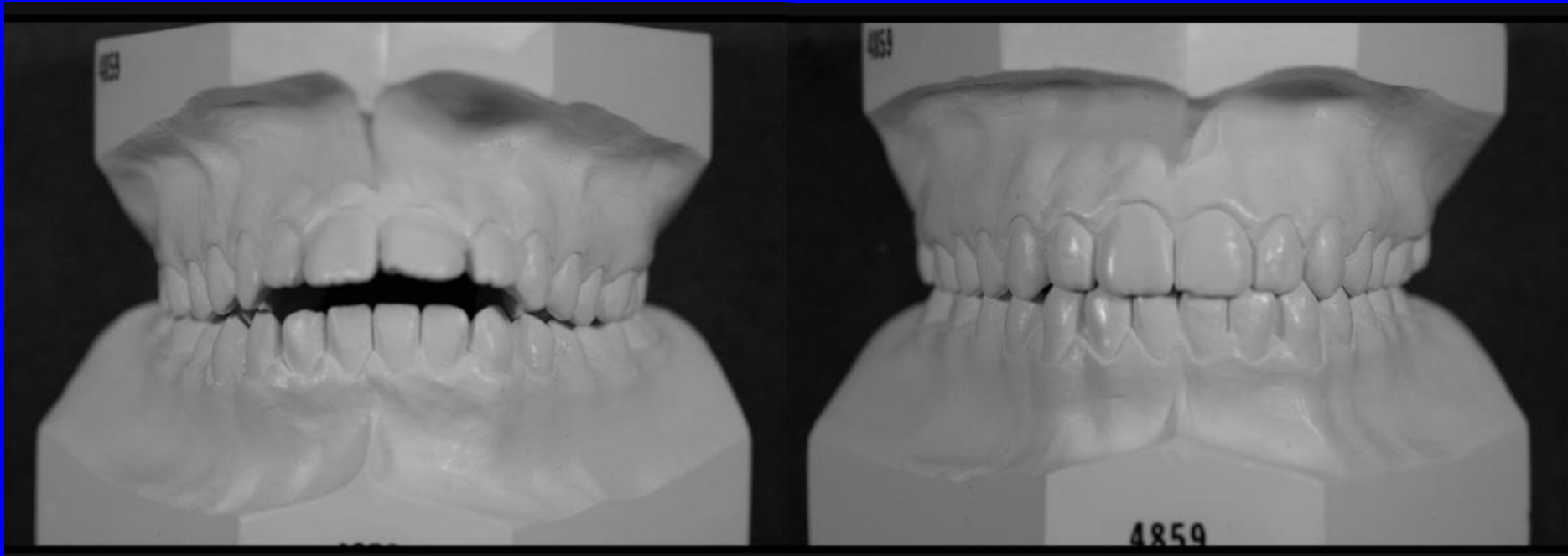




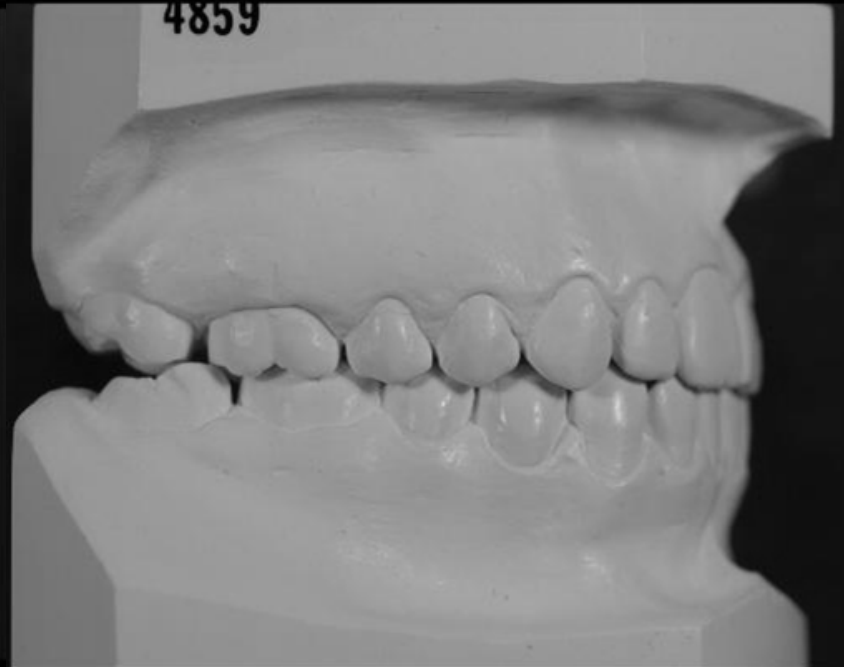
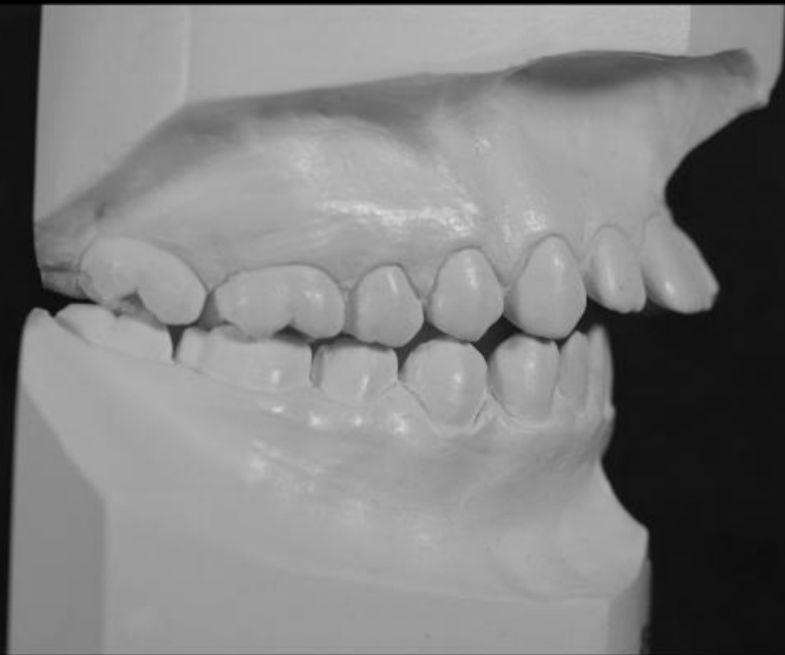
M. Baxter



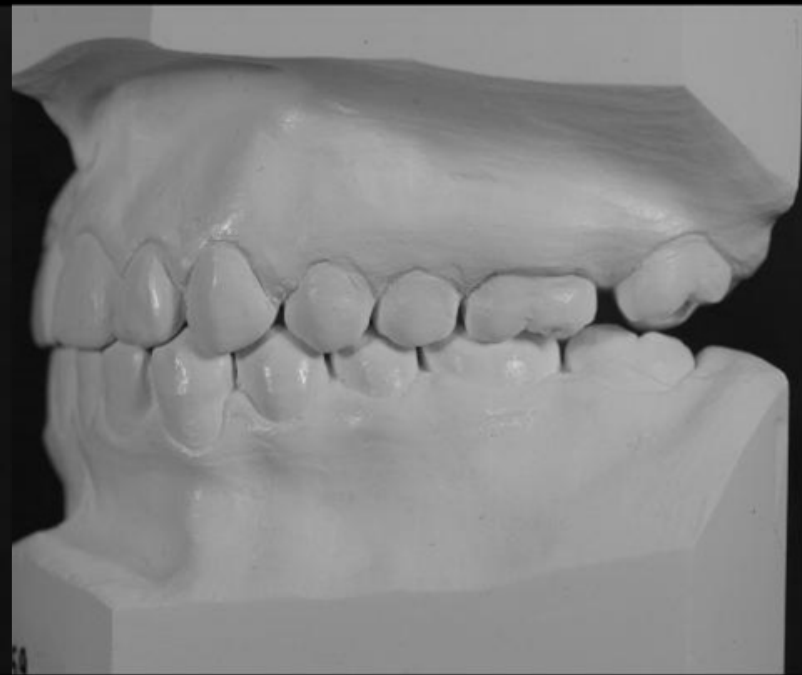
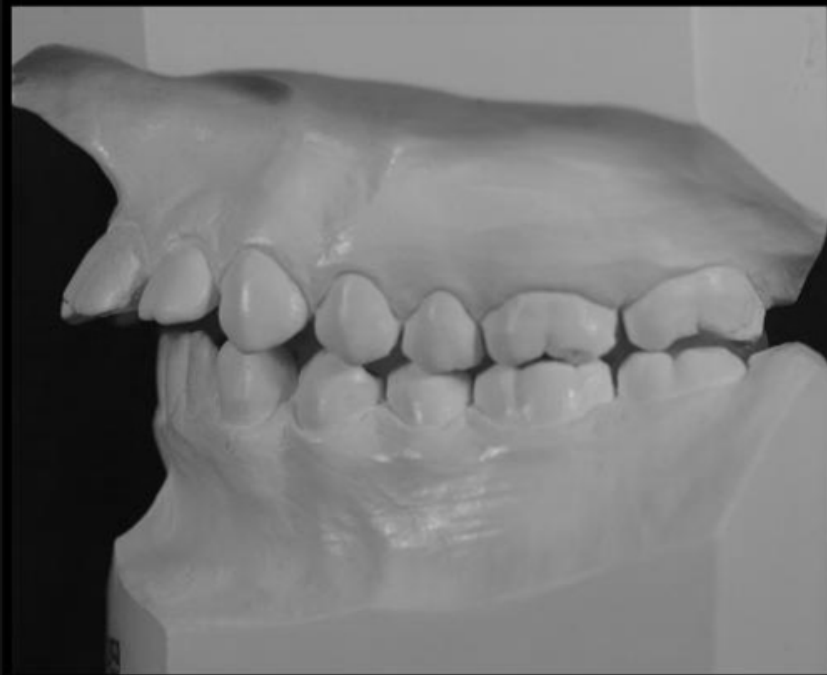
M. Baxter



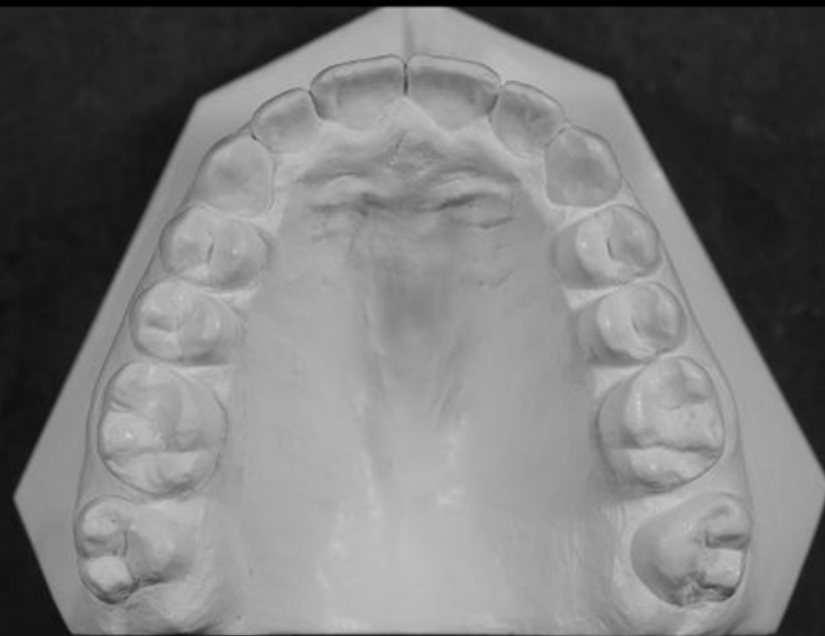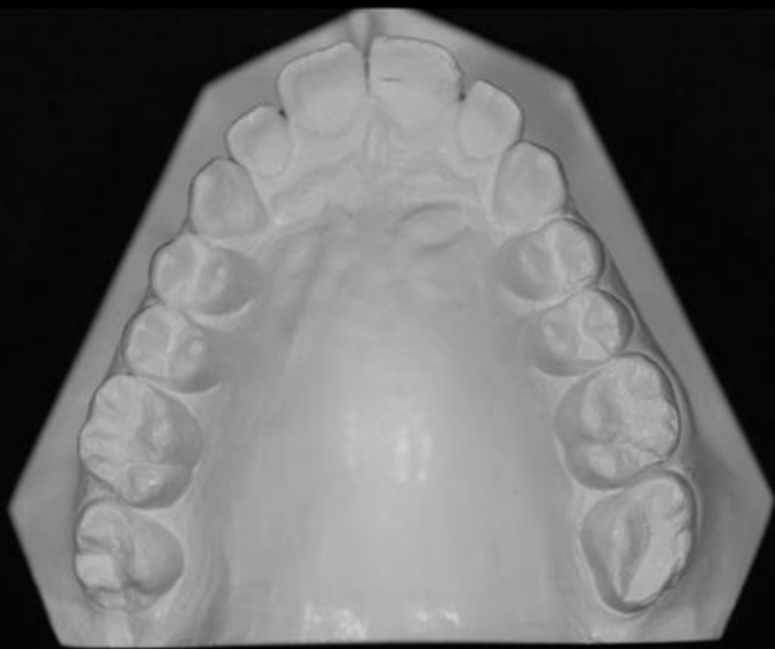
M. Baxter



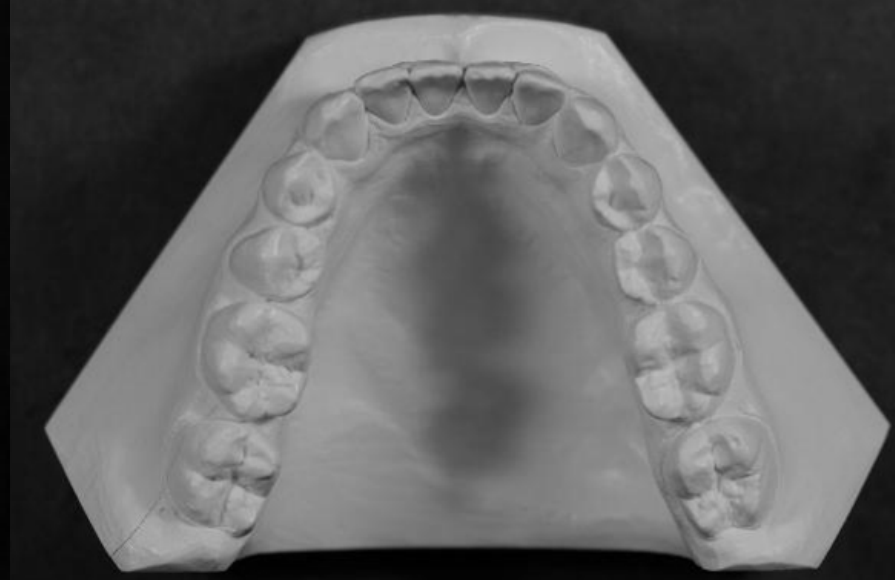
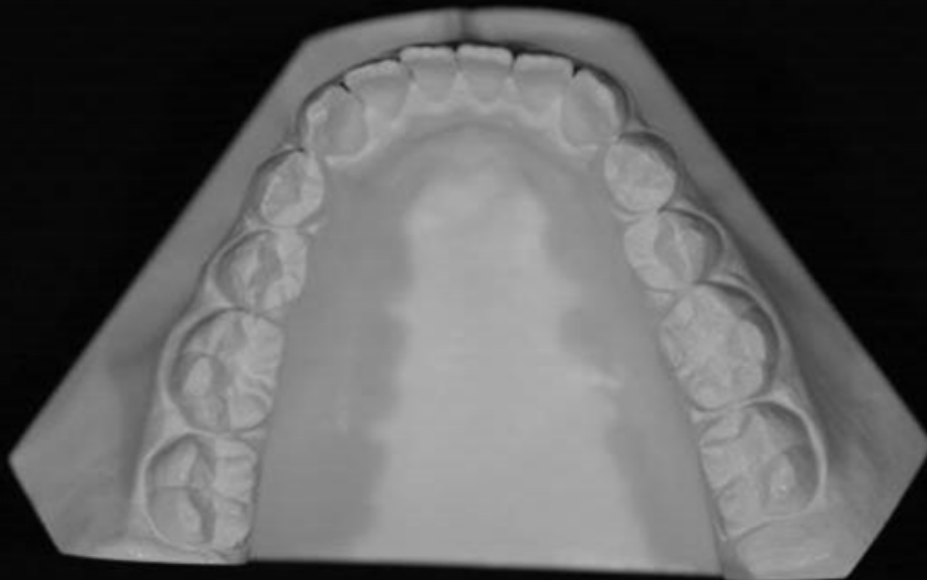
M. Baxter



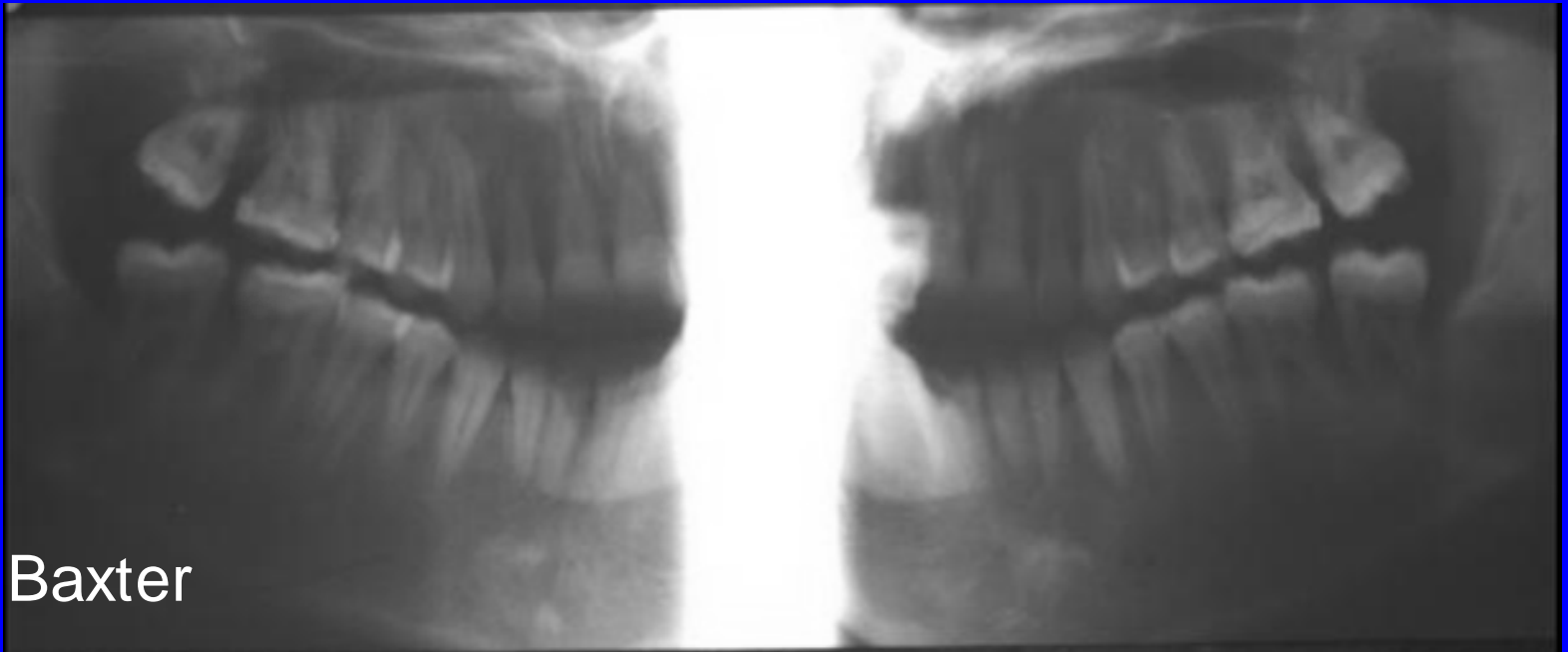
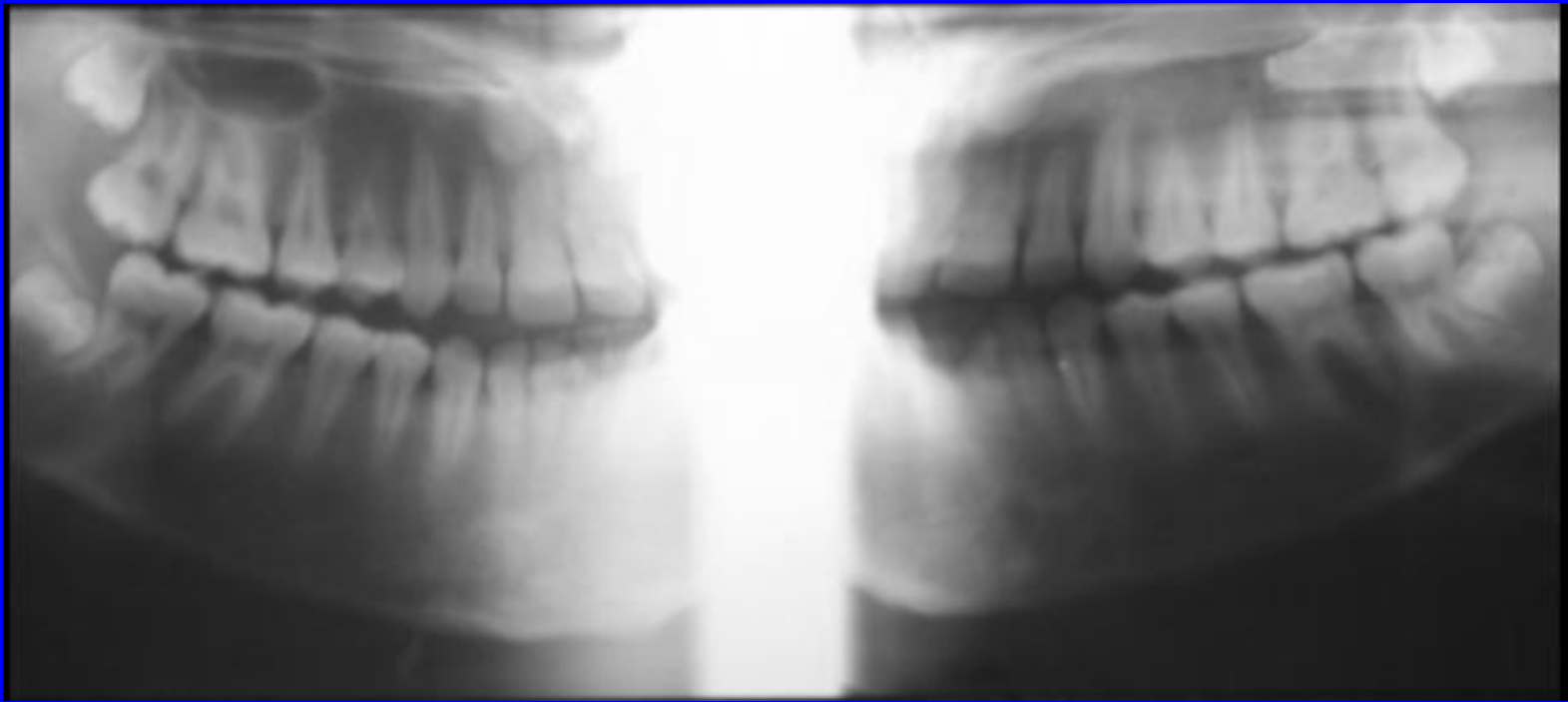
M. Baxter



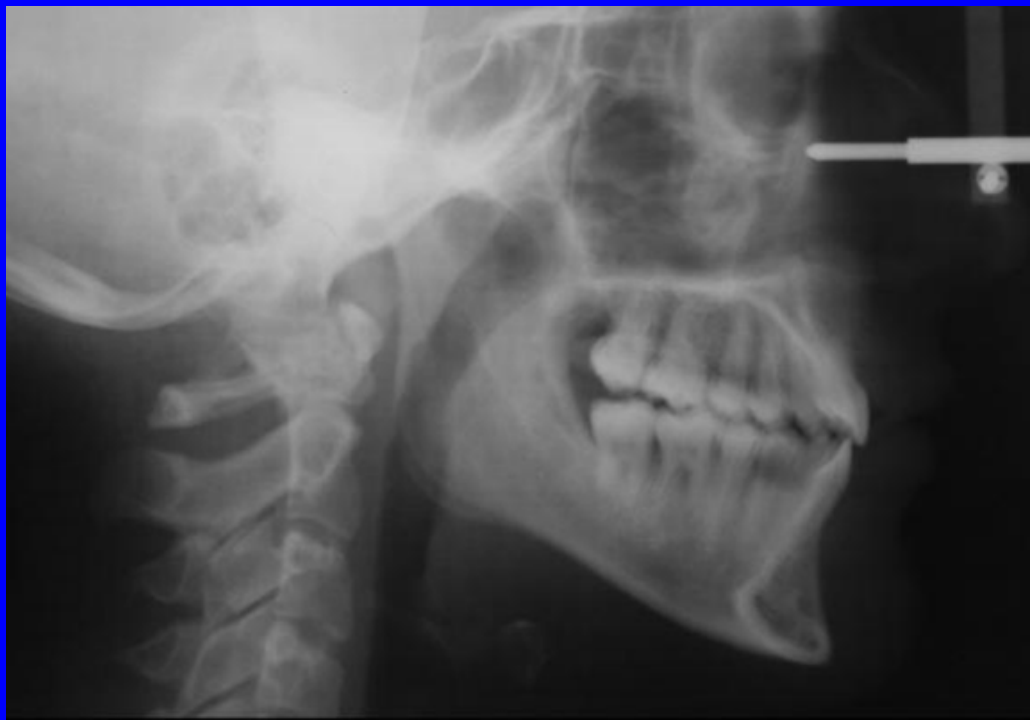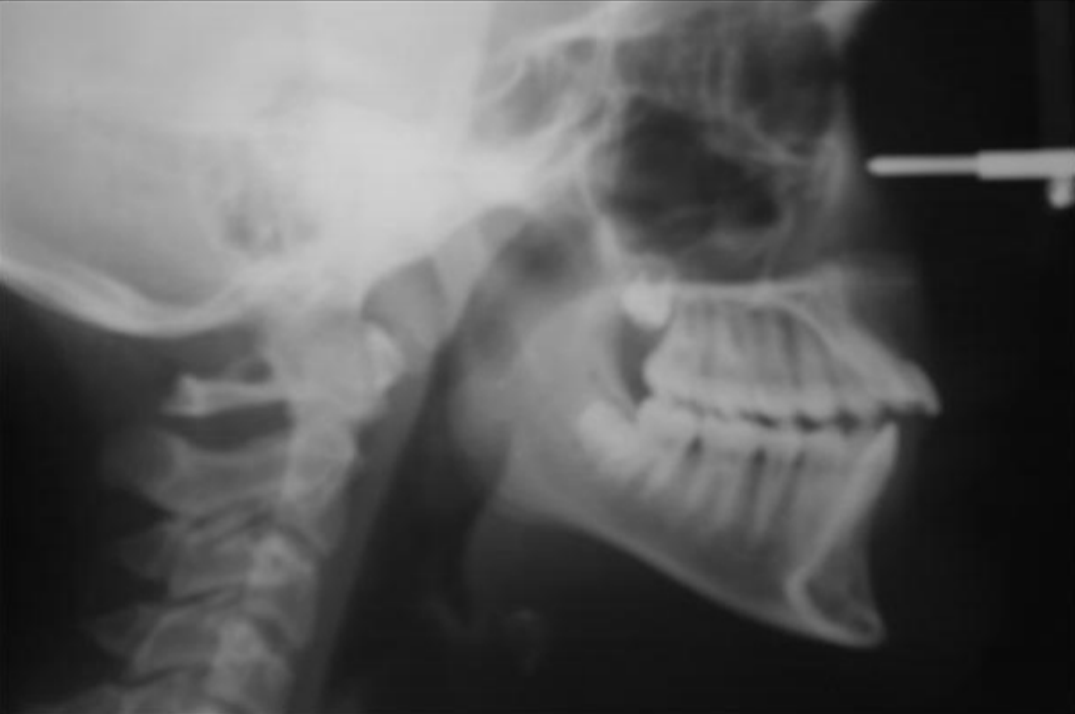M. Baxter



M. Baxter



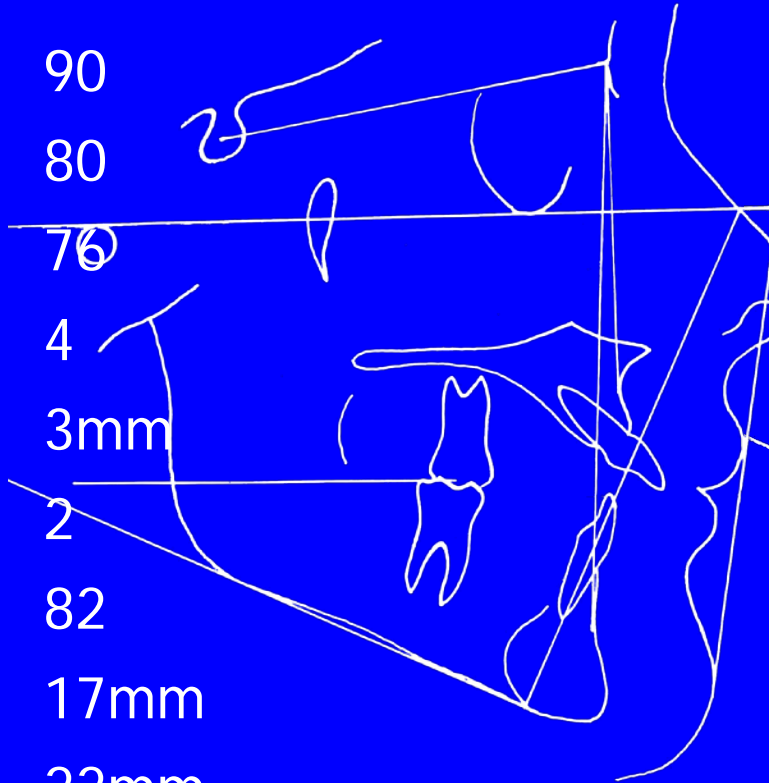M. Baxter



M. Baxter

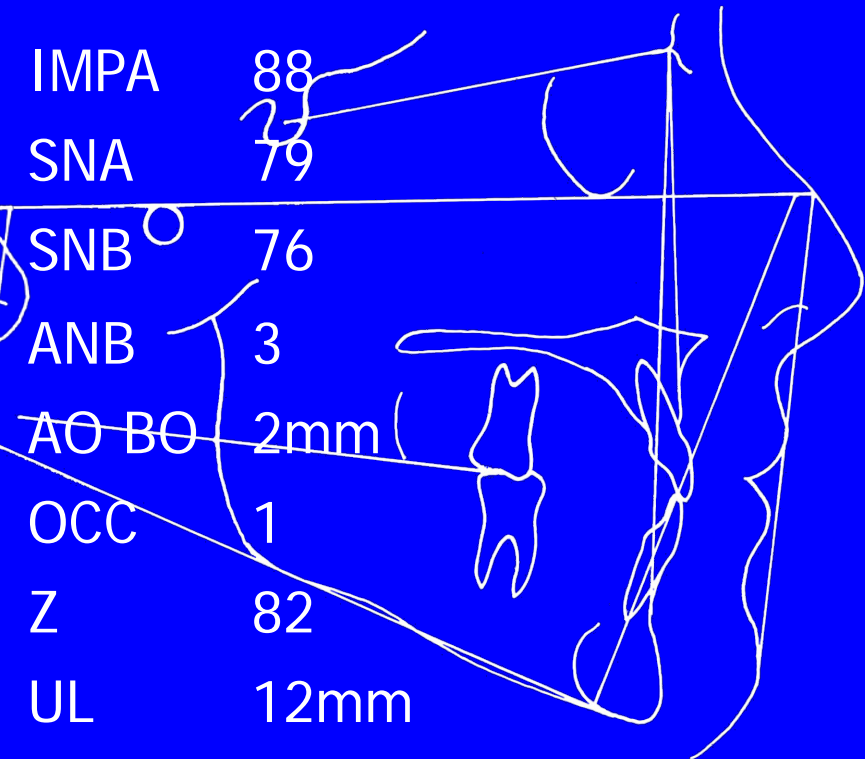
M. Baxter Pretreatment

FMIA	66
FMA	24
IMPA	90
SNA	80
SNB	76
ANB	4
AO BO	3mm
OCC	2
Z	82
UL	17mm
TC	22mm
PFH	45mm
AFH	66mm
INDEX	.68

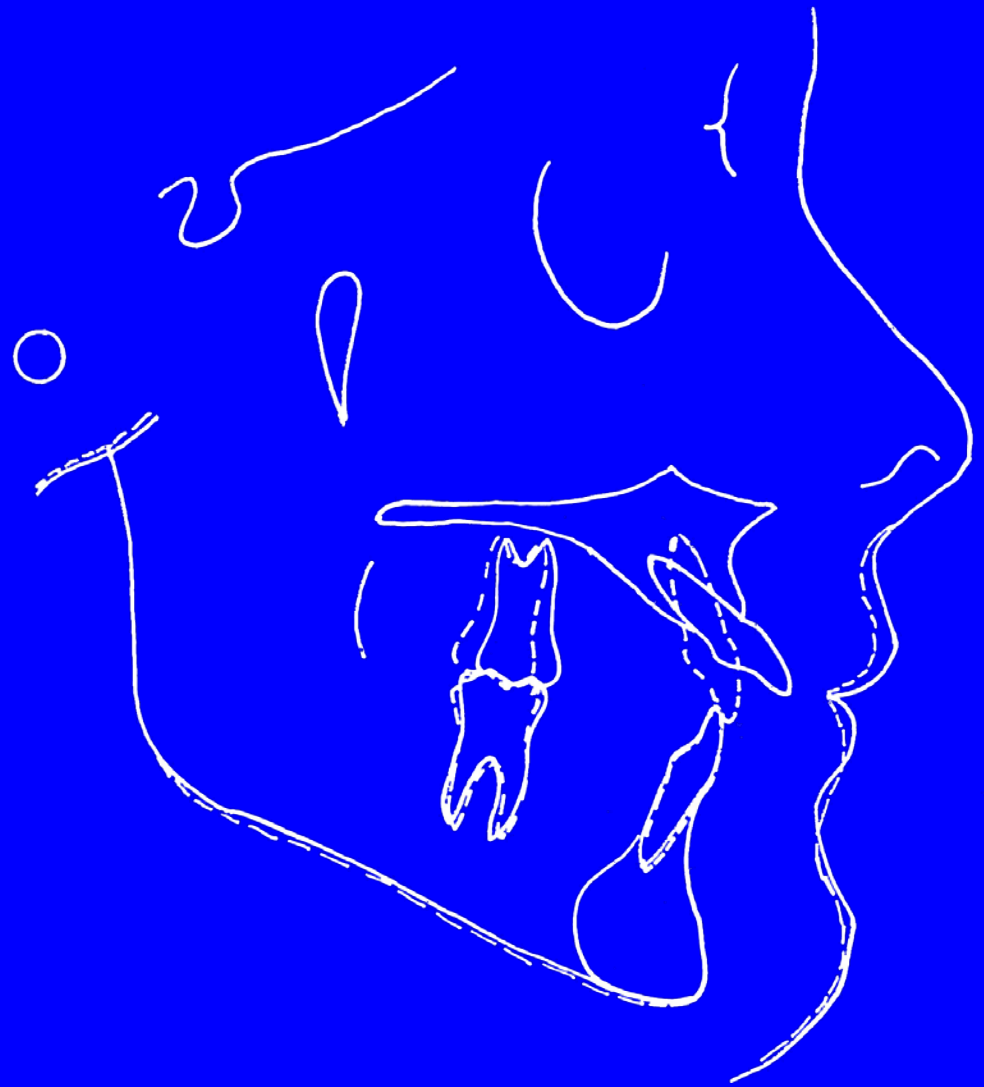
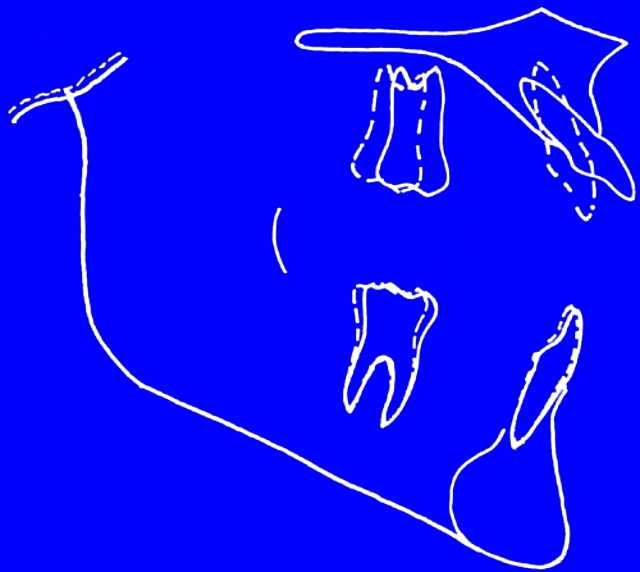


M. Baxter Posttreatment

FMIA	68
FMA	24
IMPA	88
SNA	79
SNB	76
ANB	3
AO BO	2mm
OCC	1
Z	82
UL	12mm
TC	18mm
PFH	46mm
AFH	68mm
INDEX	.67



M. Baxter

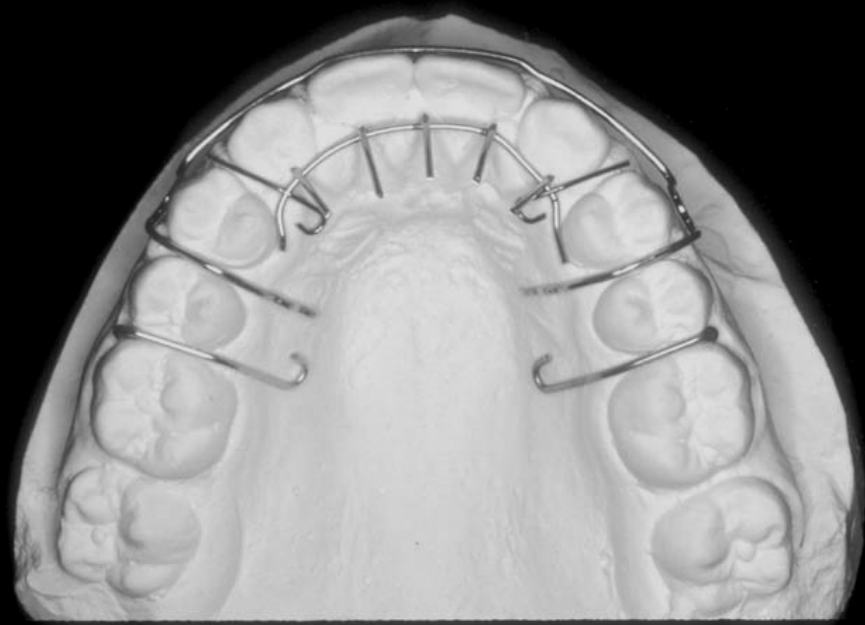


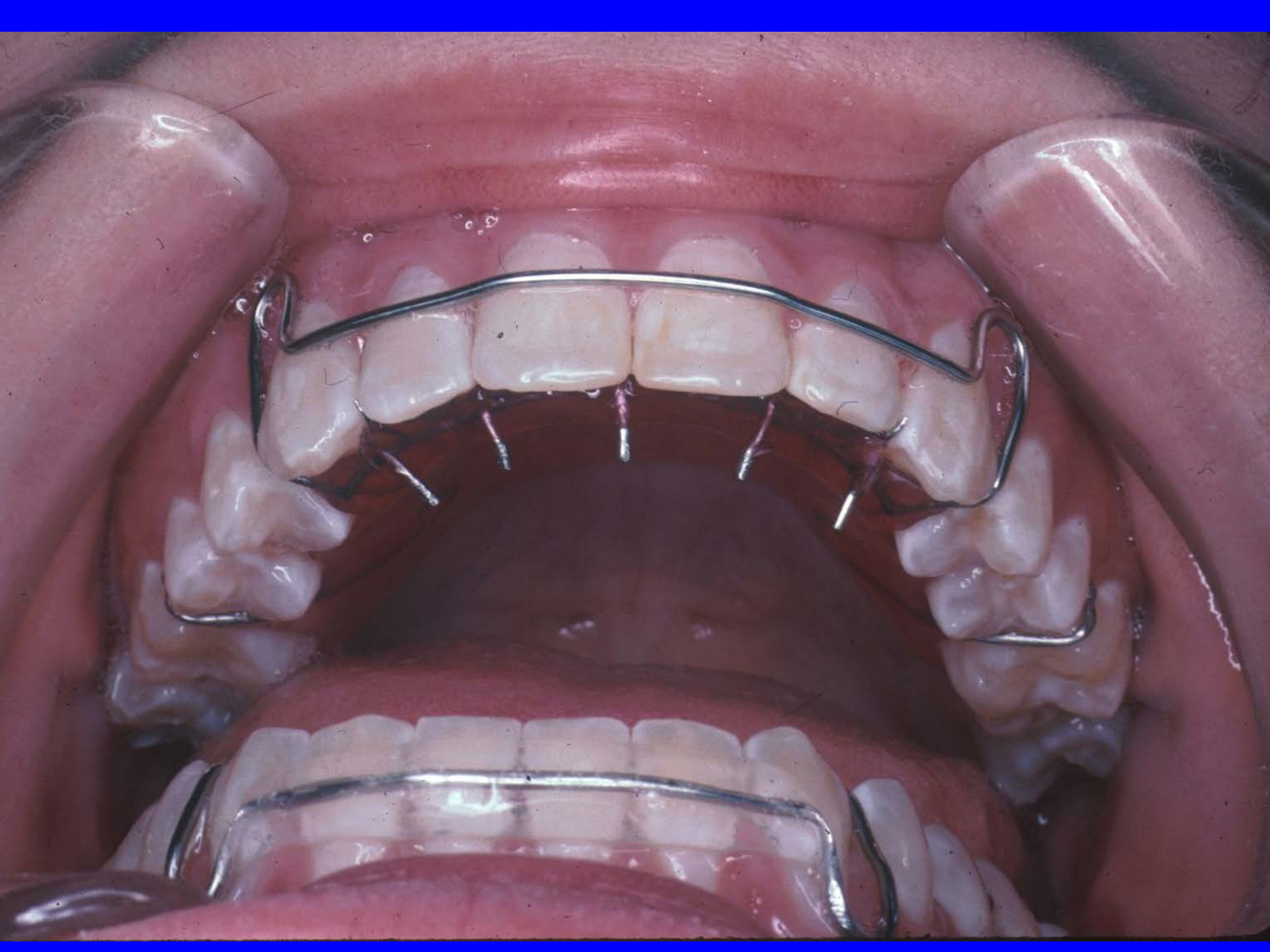Pretreatment ———

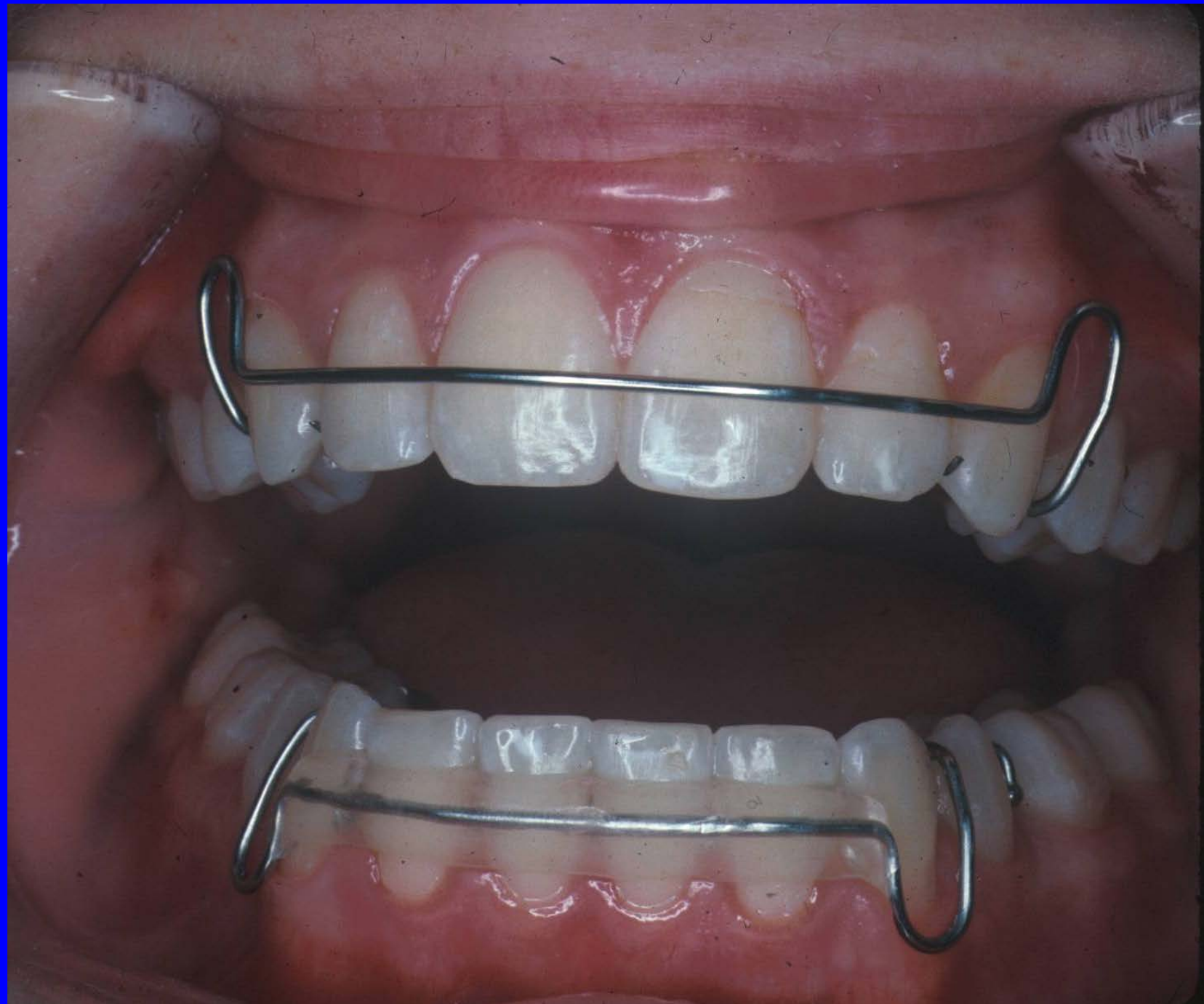Posttreatment - - - -

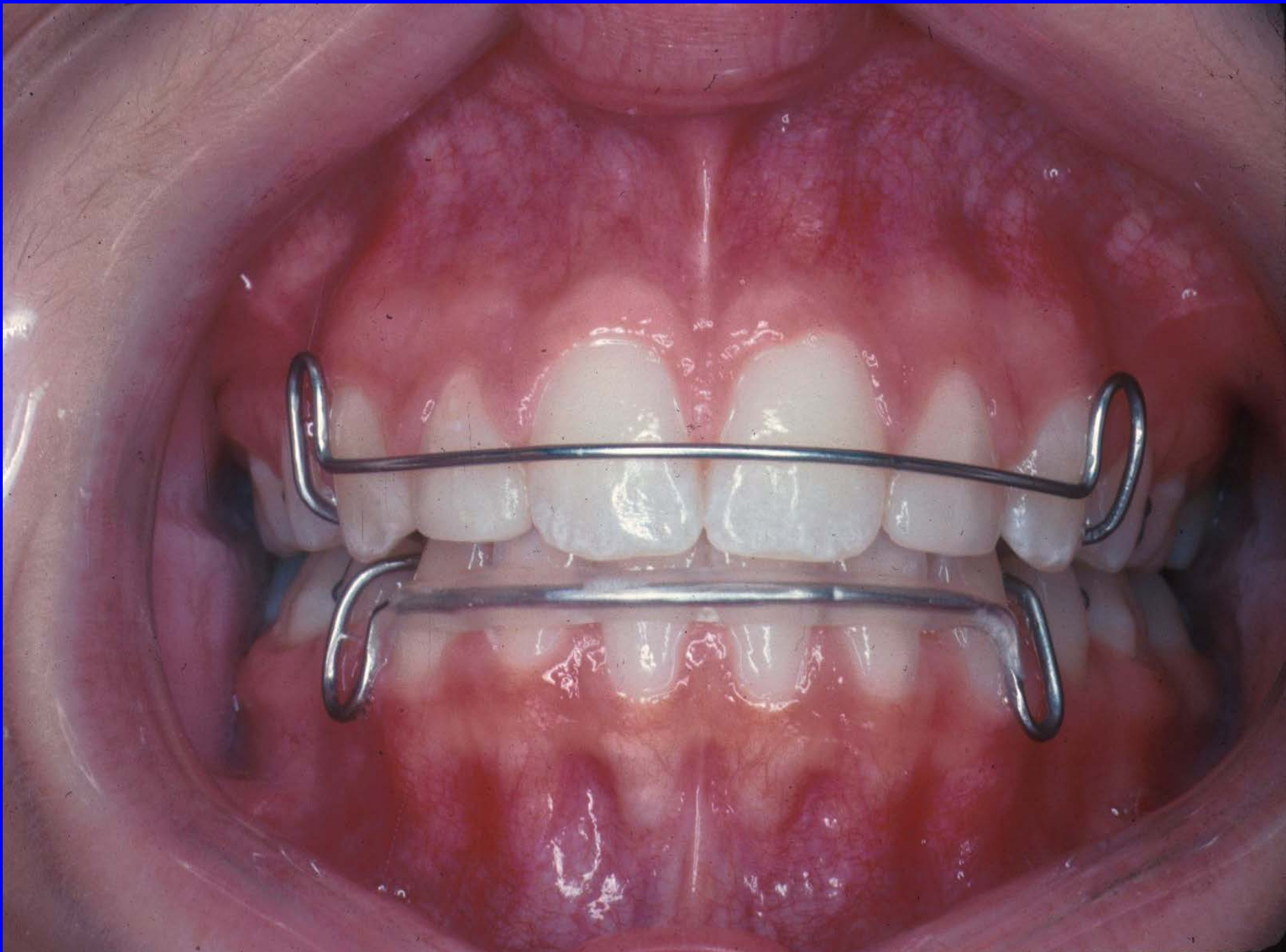


M. Baxter











M. Baxter



M. Baxter

POSTTREATMENT:

After the extraction of the third molars headgear was worn to both the mandibular and maxillary arches. The tongue problem was addressed with a tongue crib.

Following mandibular anchorage preparation the maxillary arch was distalized with Class II elastics and headgear. The tongue crib was incorporated into the maxillary Hawley retainer.