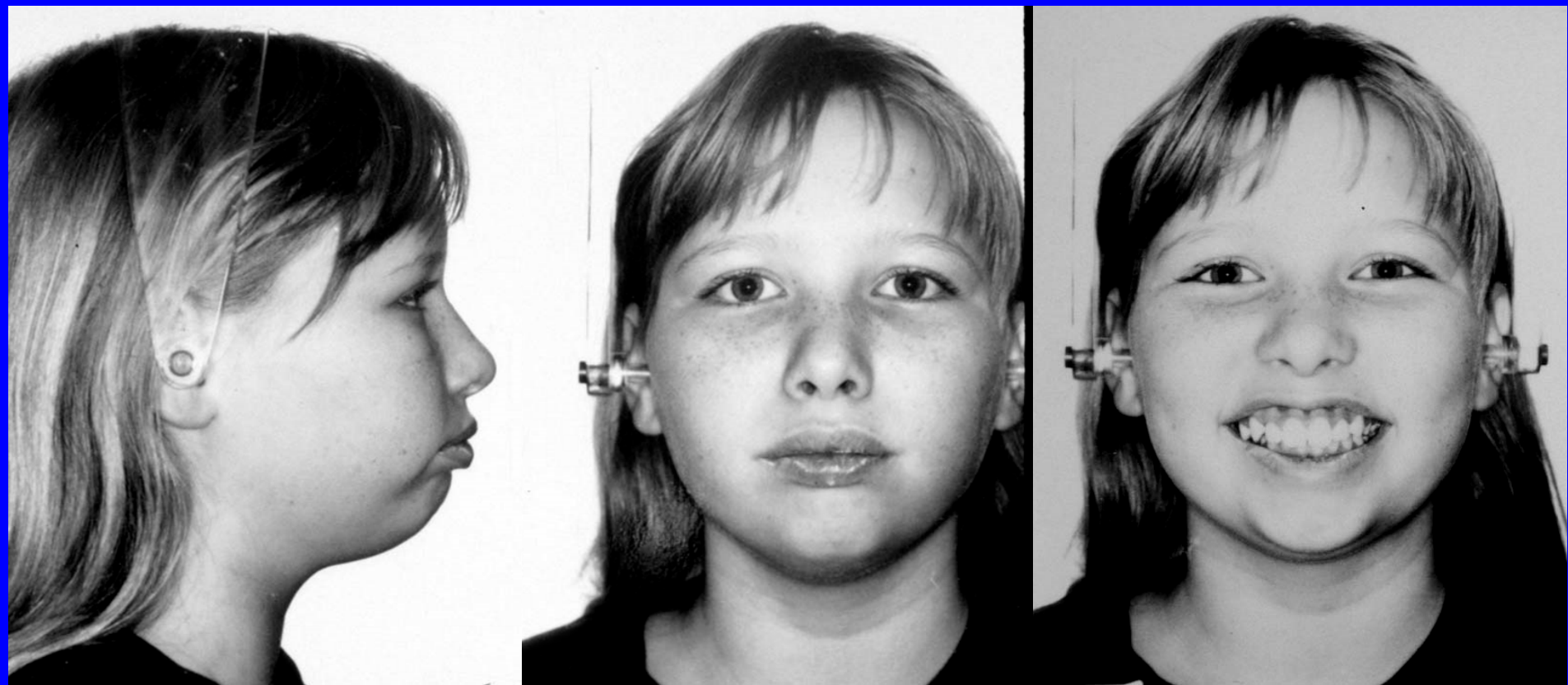

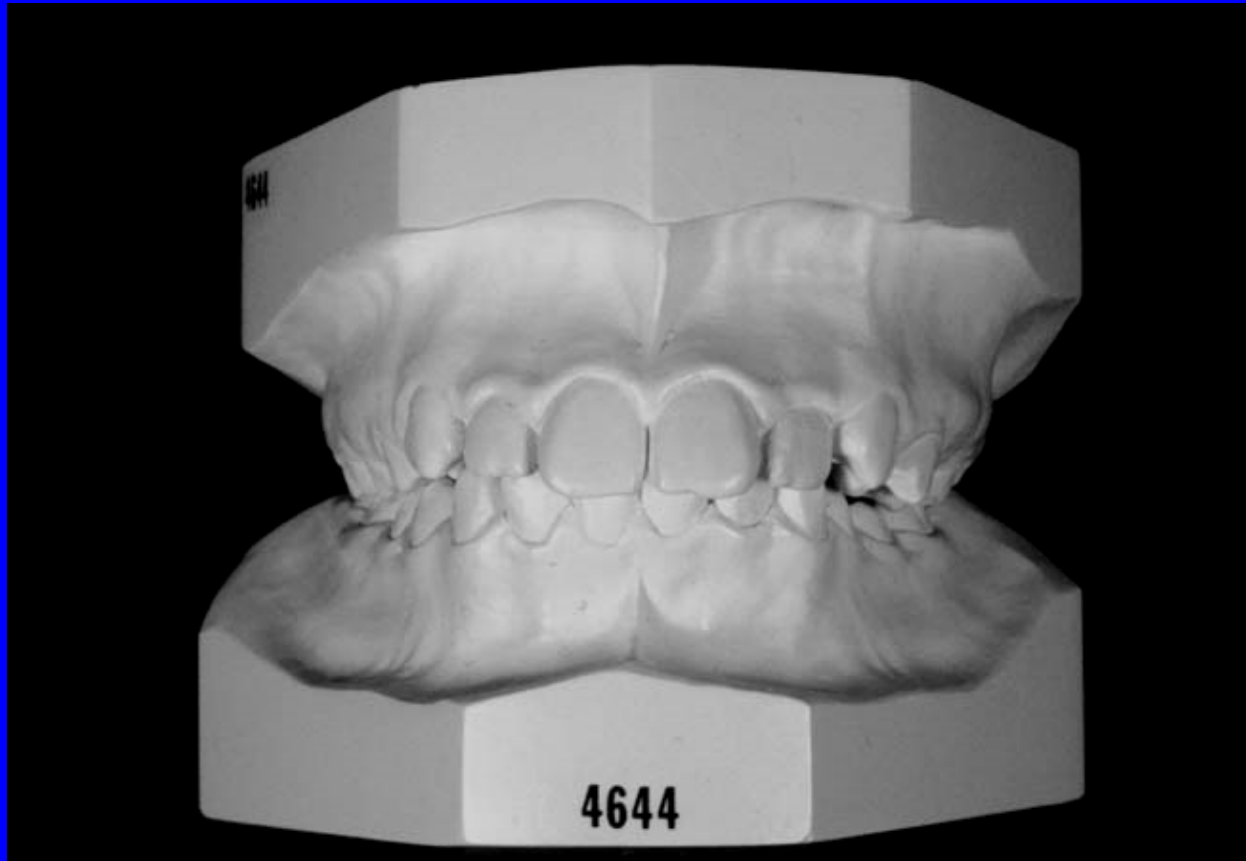
M. KATAN

PRETREATMENT RECORDS

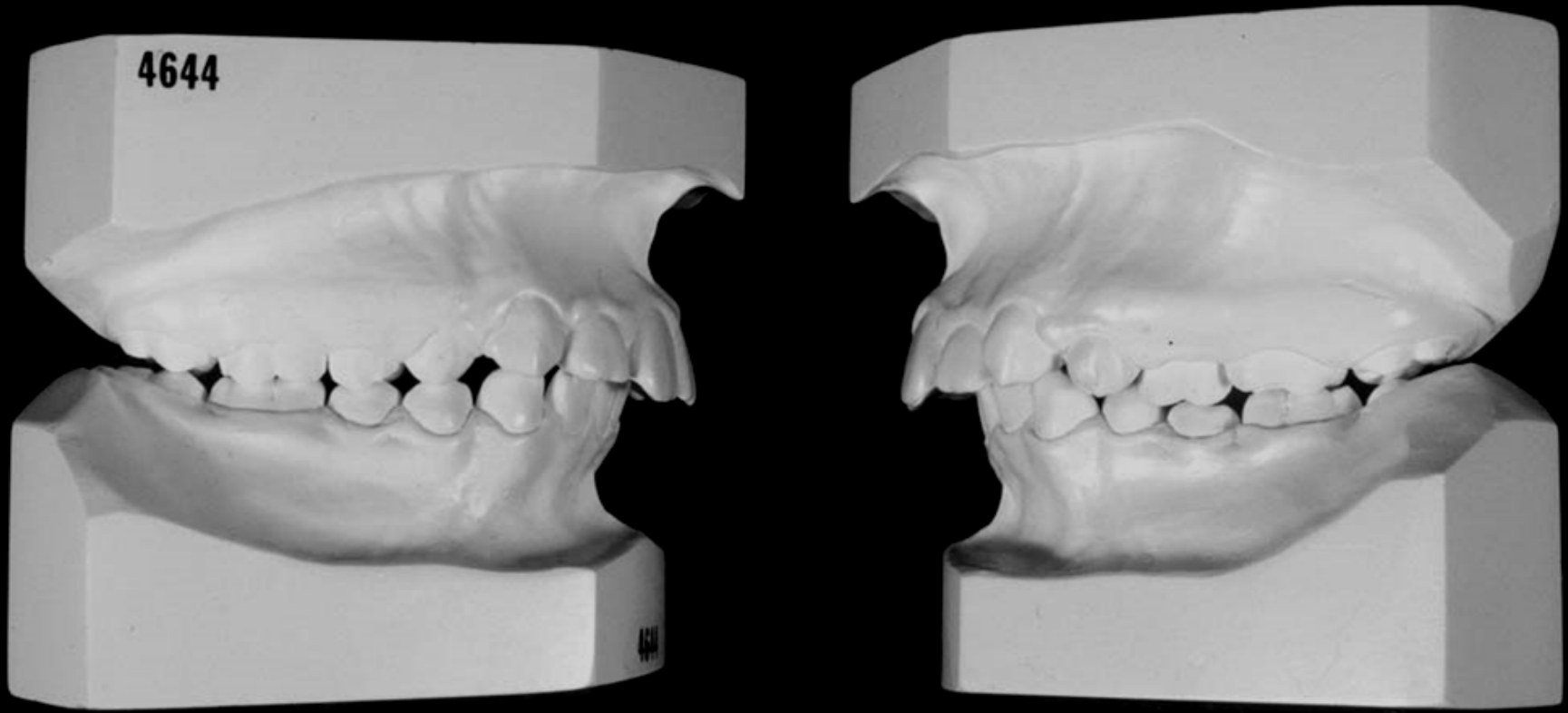
The patient is a twelve year old female with a significant anteroposterior discrepancy (ANB of 10 degrees), a Class II occlusion and marked facial imbalance. Note the “gingival smile”.



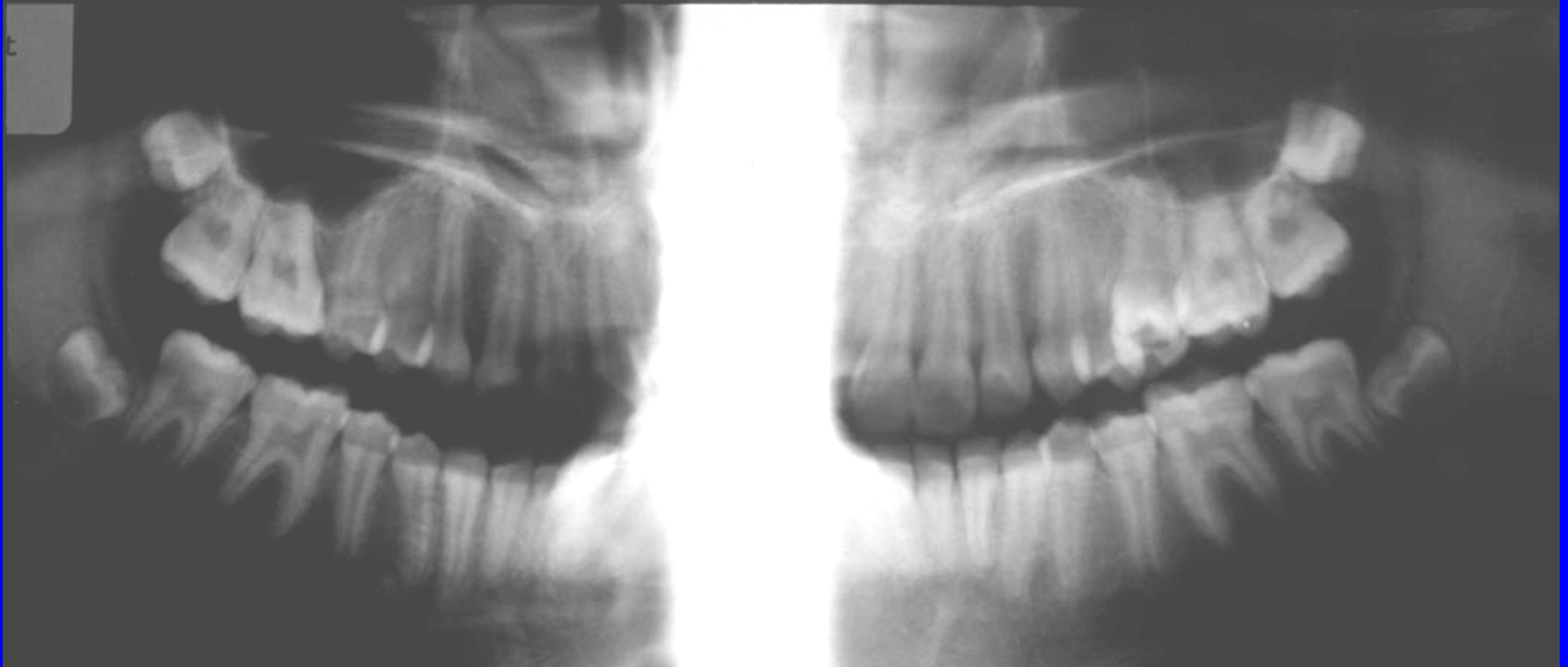
M. Katen



M. Katen



M. Katen



M. Katen

M. Katen Pretreatment

FMIA 50

FMA 25

IMPA 105

SNA 93

SNB 83

ANB 10

AO BO 7mm

OCC 8

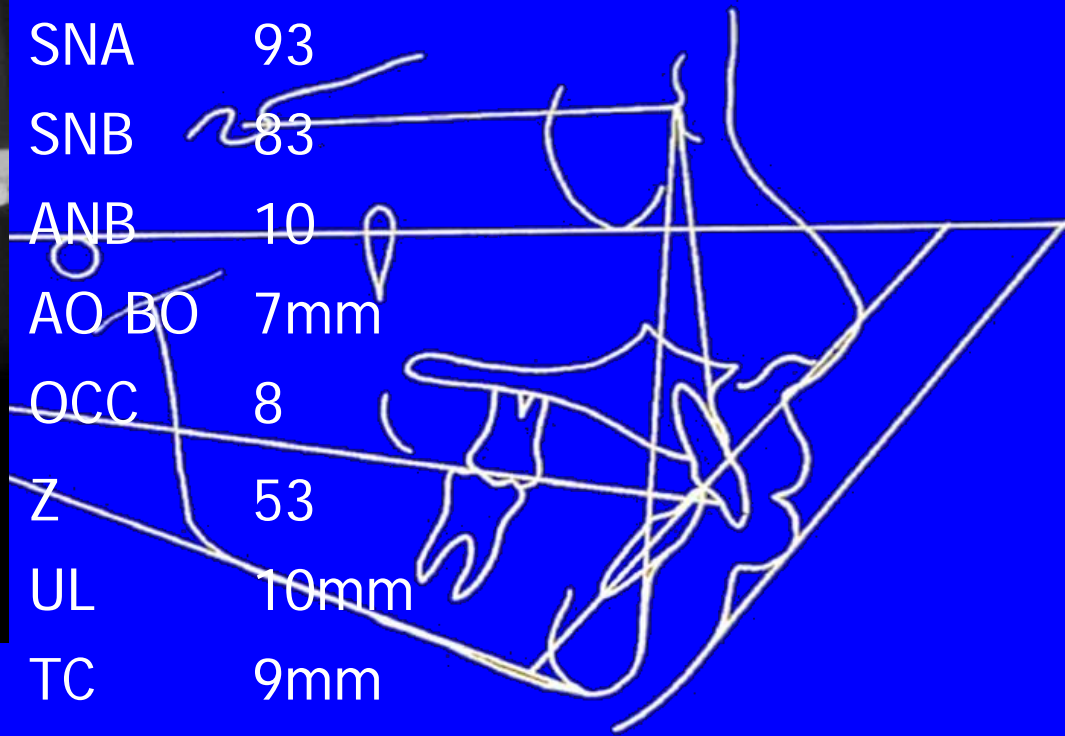
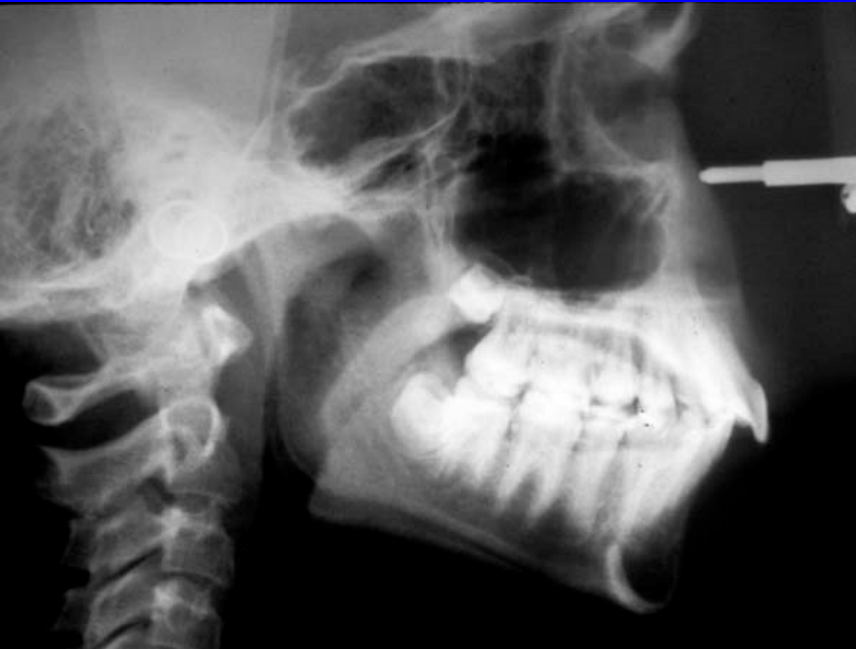Z 53

UL 10mm

TC 9mm

PFH 44mm

AFH 58mm



CRANIAL FACIAL ANALYSIS

	CEPH.	DIFFICULTY	
NORMAL RANGE	VALUE	FACTOR	DIFF
FMA 22°- 28°	25	5	0
ANB 1°- 5°	10	15	75
Z ANGLE 70°- 80°	53	2	34
OCC PLANE 8°-12°	8	3	0
SNB 78°-82°	83	5	0
PFH-AFH .65-.75	.75	3	0
M. Katen			
			C.F. DIFFICULTY TOTAL
			<u>109</u>

TOTAL SPACE ANALYSIS

		WEIGHTED	
		VALUE	DIFF
ANTERIOR			
TOOTH ARCH DISC.	1.0	1.5	1.5
HEADFILM DISC.	13.6	1	13.6
TOTAL	14.6		15.1
MID ARCH			
TOOTH ARCH DISC.	0	1.0	0
CURVE OF SPEE	2.0	1.0	2.0
TOTAL	2.0		
OCCLUSAL DISHARMONY			
(CLASS II OR CLASS III)	8.0	2.0	16.0
M. Katen		TOTAL	18.0

TOTAL SPACE ANALYSIS

		DIFFICULTY	
		FACTOR	DIFF
POSTERIOR			
TOOTH ARCH DISC.	14	.5	7
(-) EXPECTED INC.	4	.5	2
TOTAL	10		5
	TOTAL S.A.		S.A. DIFF
ANTERIOR	14.6		15.1
MID ARCH	2.0		18.0
POSTERIOR	10.0		5.0
TOTAL	26.6		38.1

M. Katen

C.F. DIFFICULTY	109.0
S.A. DIFFICULTY	37.1
TOTAL DIFFICULTY	146.1

M. Katen

DIFFERENTIAL DIAGNOSIS AND CLINICAL ANALYSIS

INDEX DIFFICULTY:

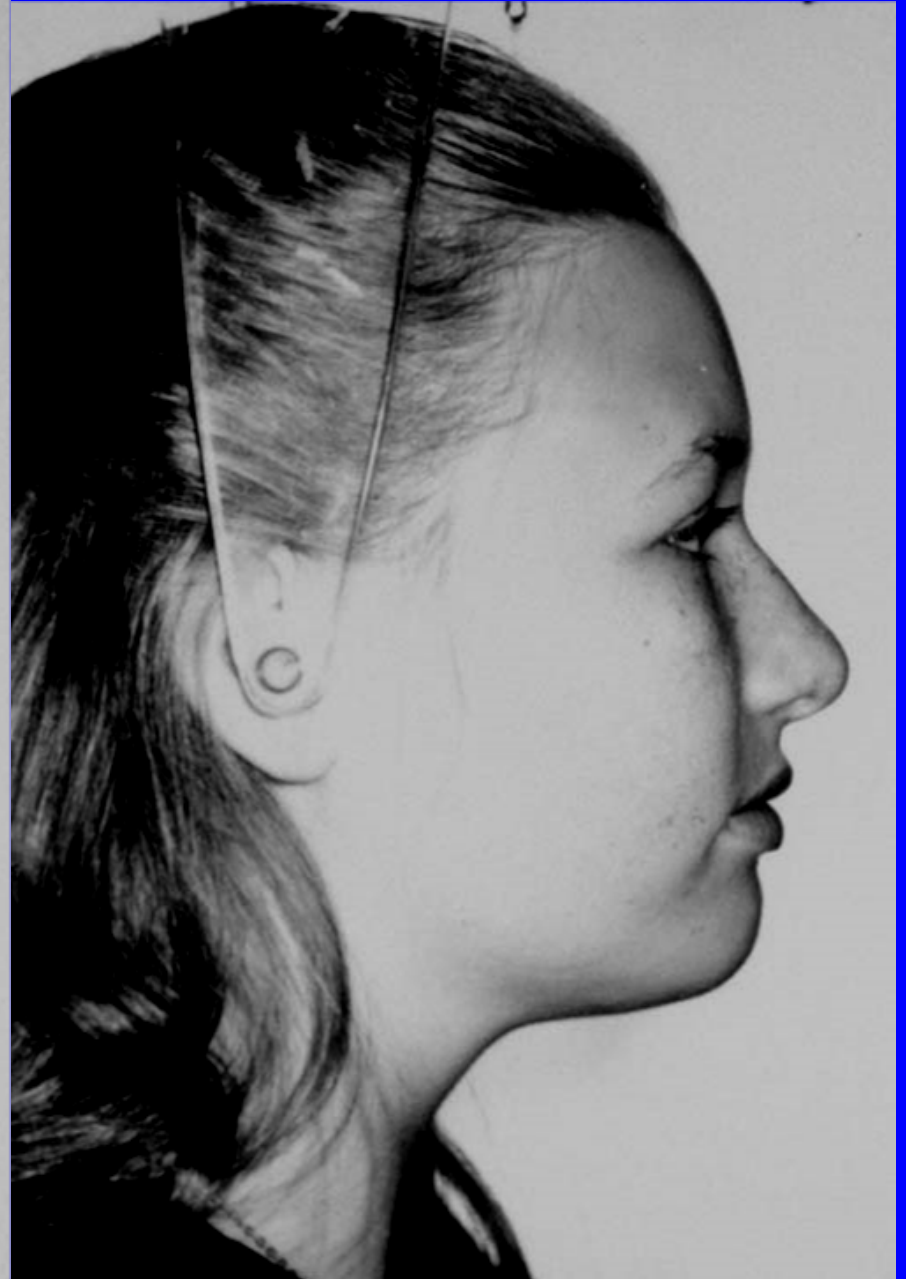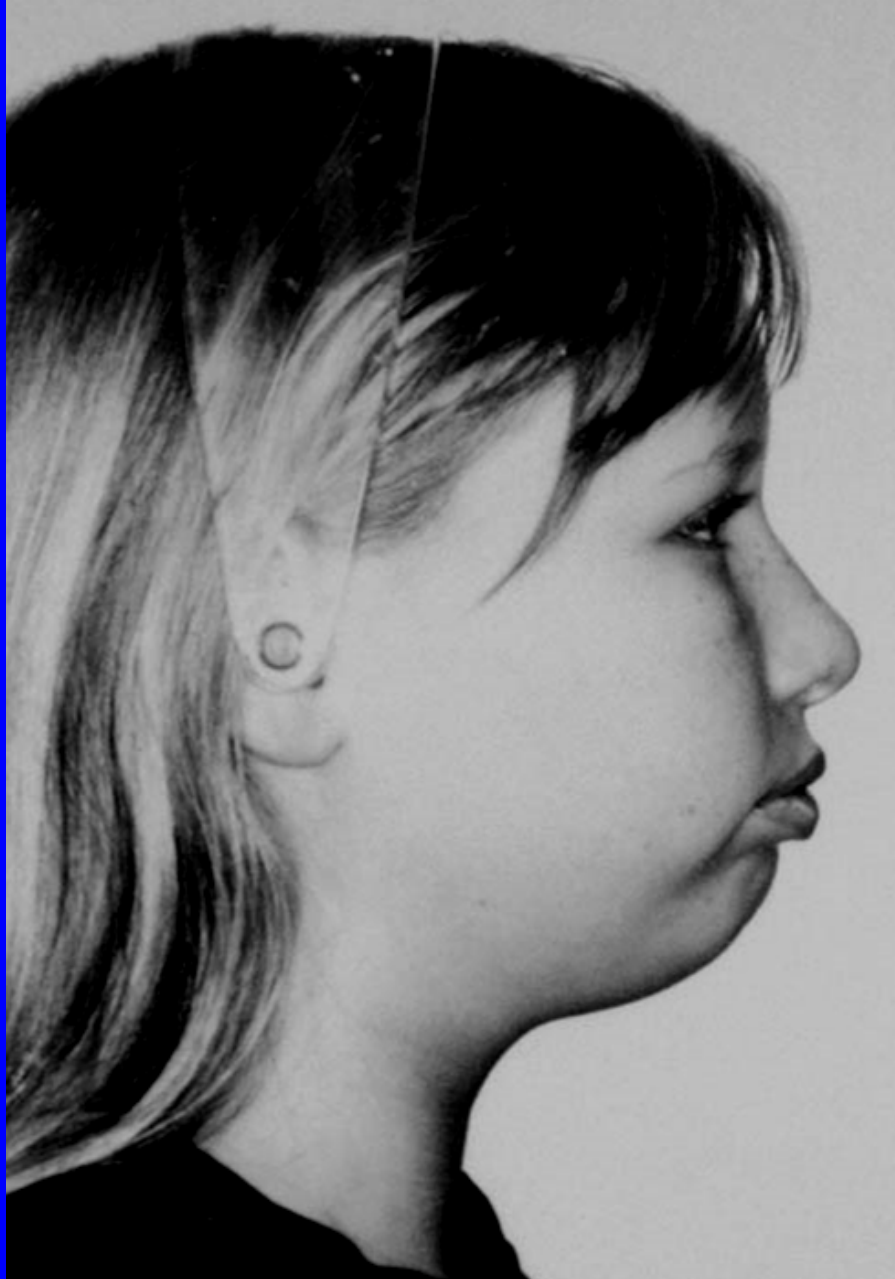MILD 0-60

MODERATE 60-120

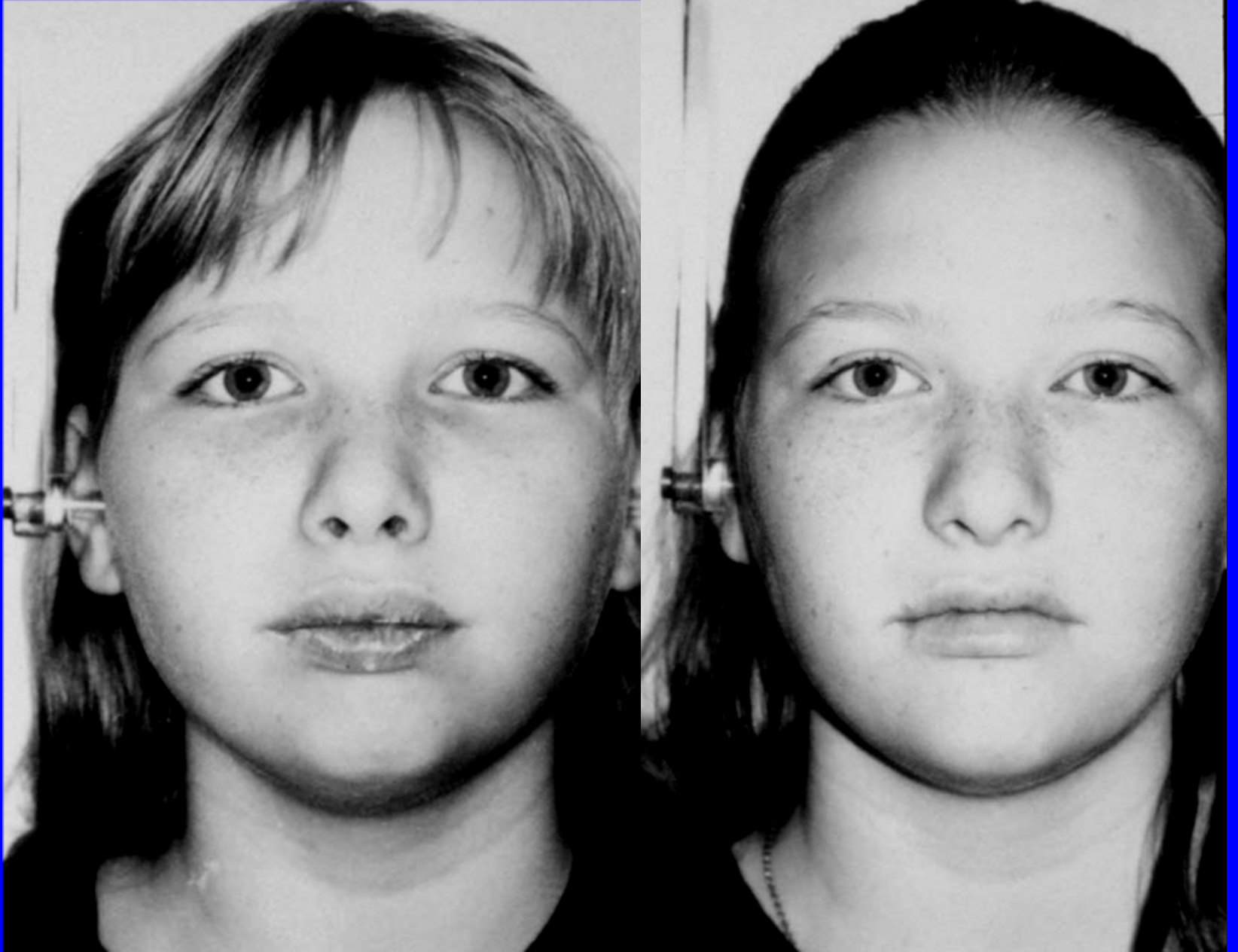SEVERE 120+

TREATMENT PLAN:

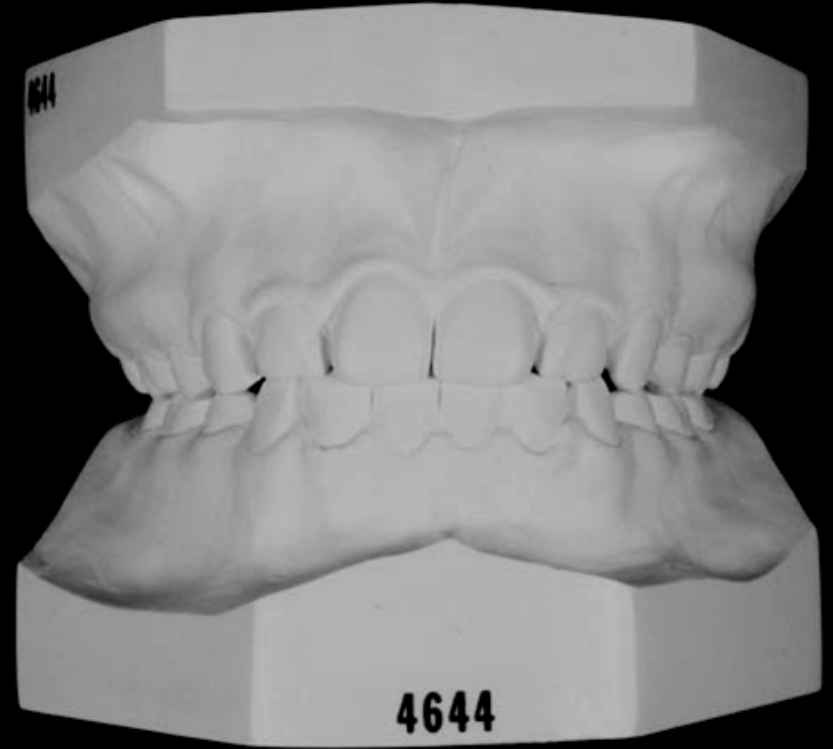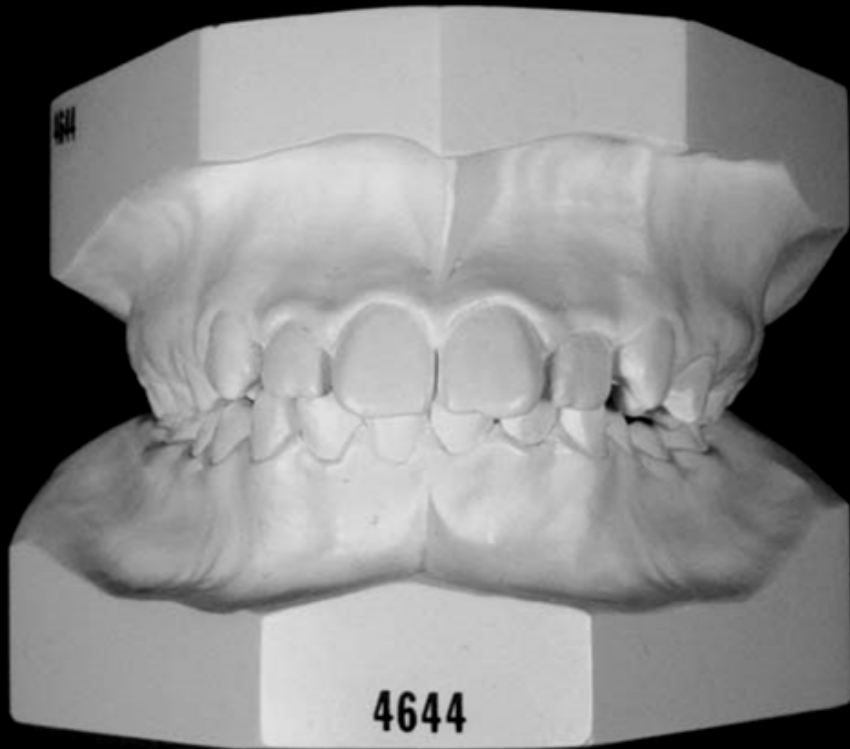
**Extract four first premolars
and treat with sequential
directional forces treatment.**



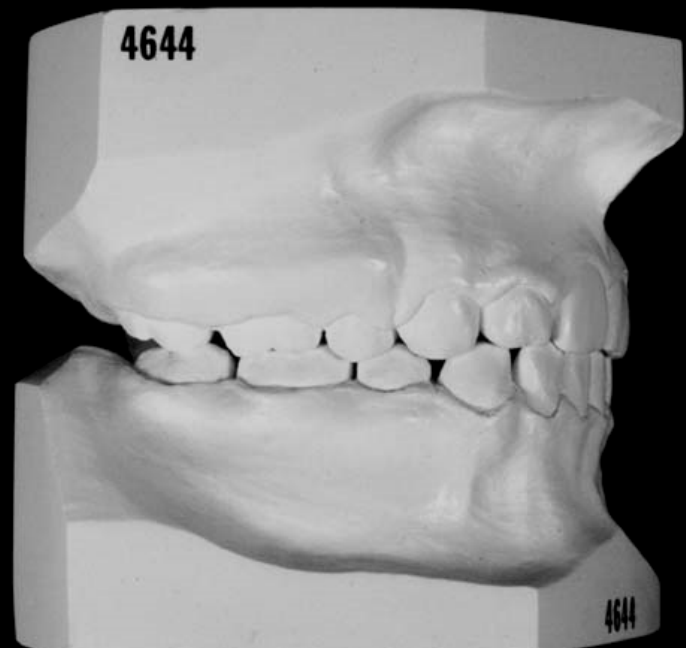
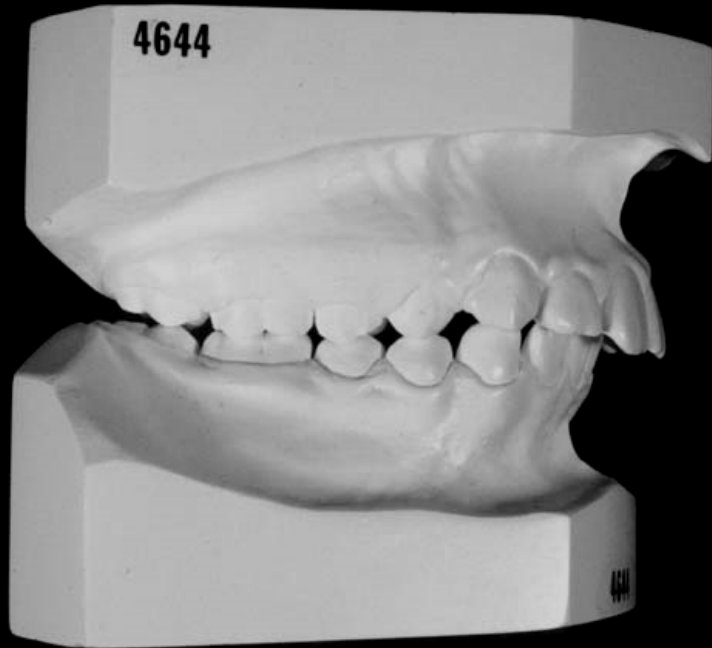M. Katen



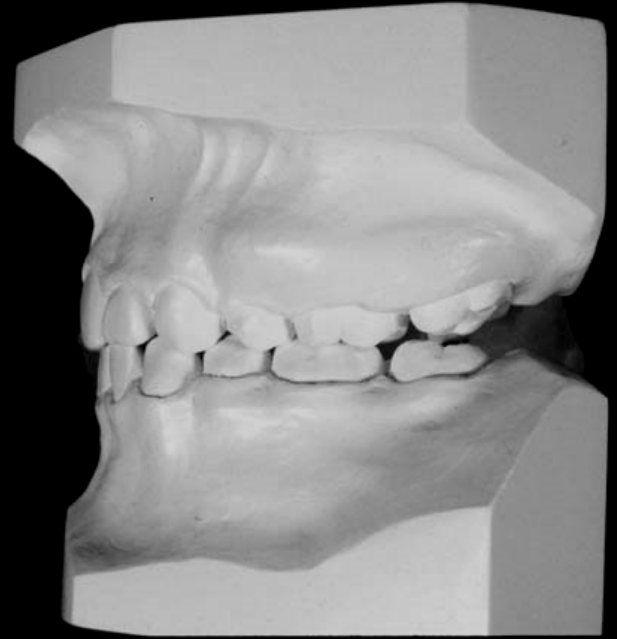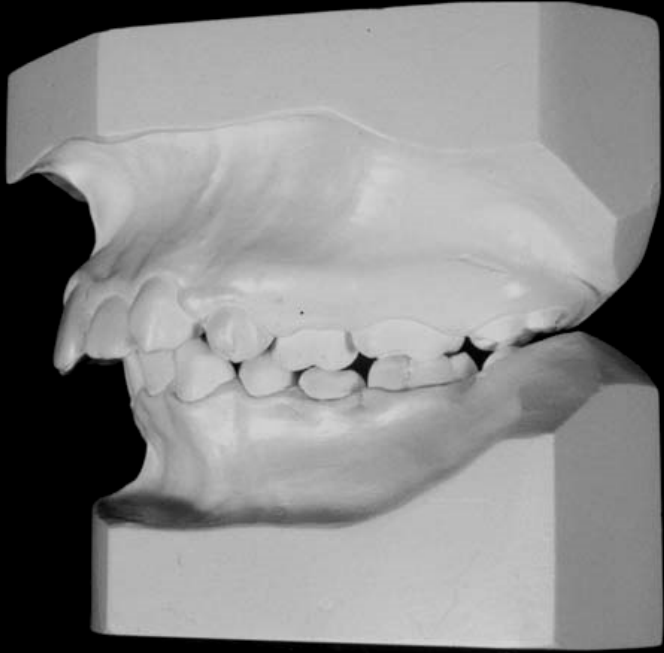
M. Katen

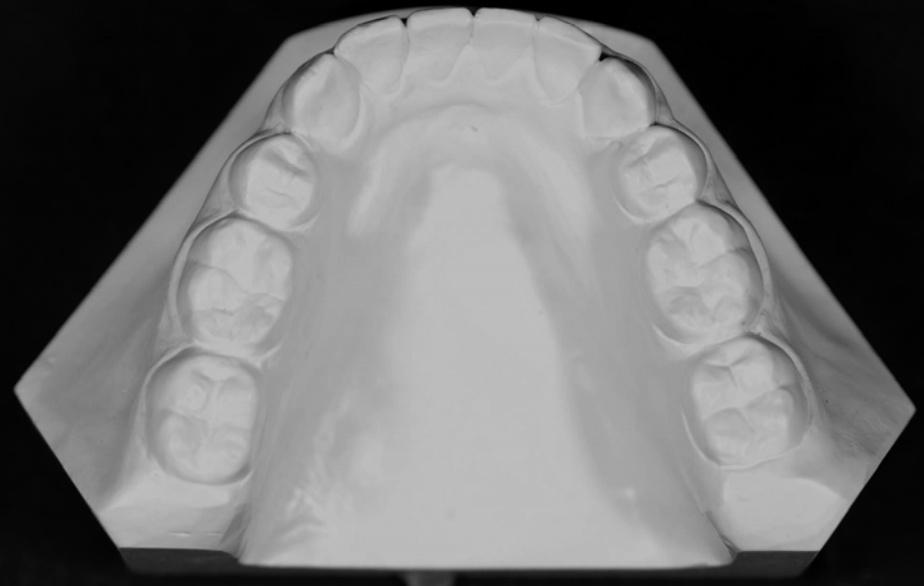
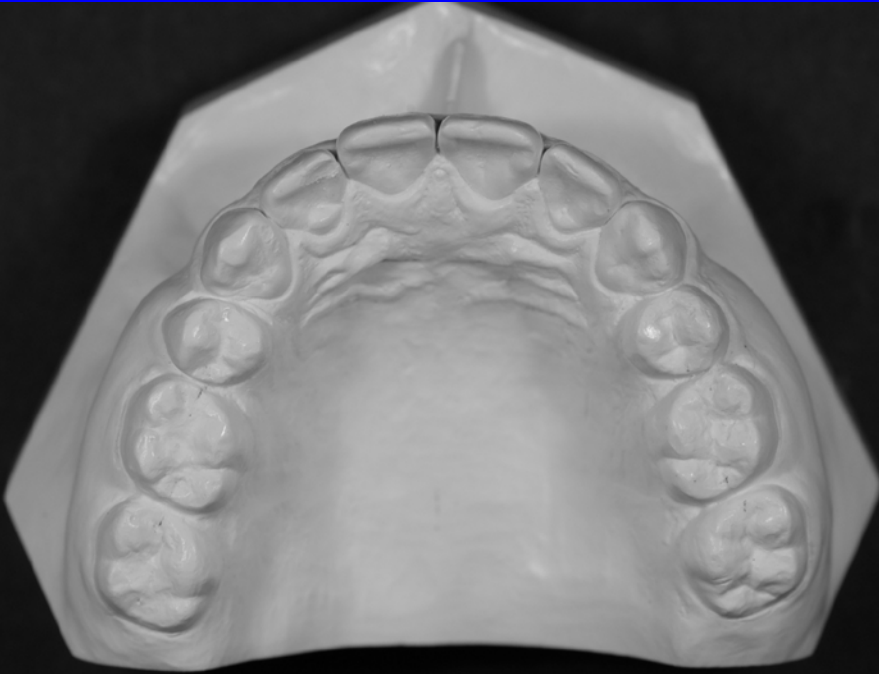


M. Katen

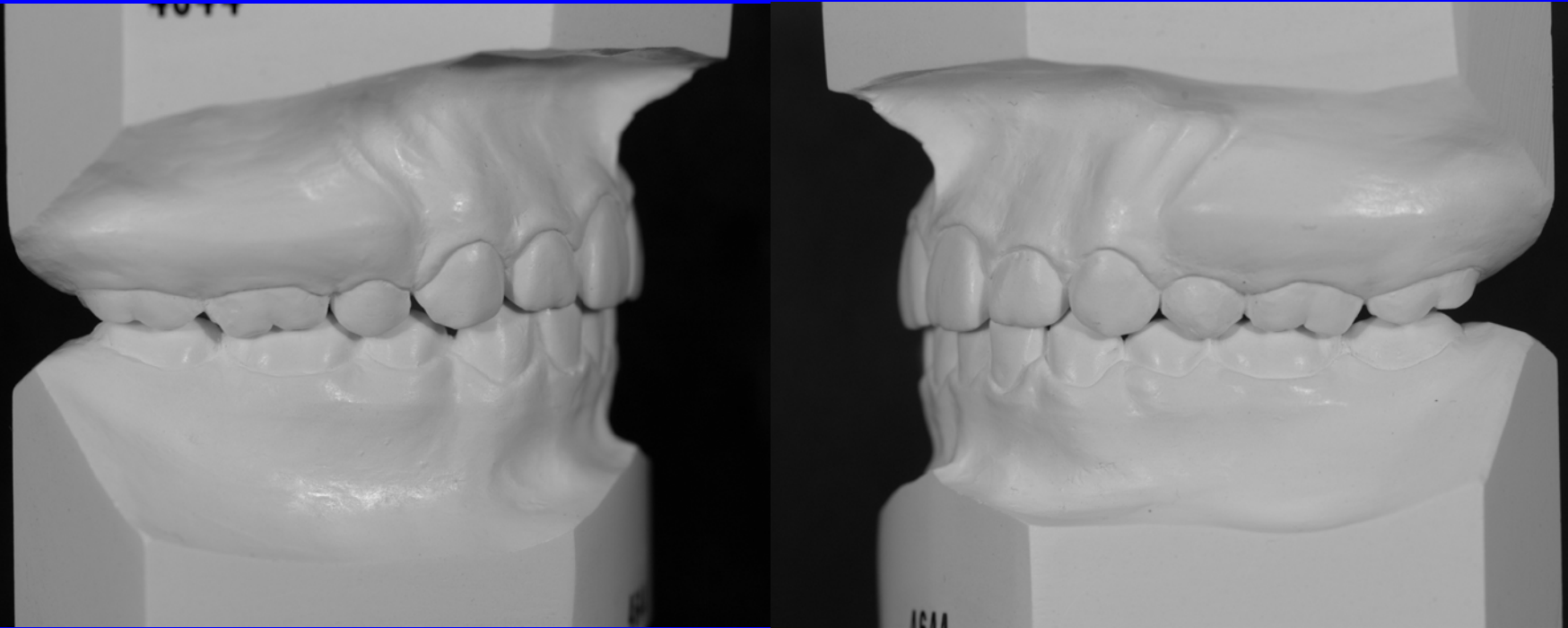


M. Katen

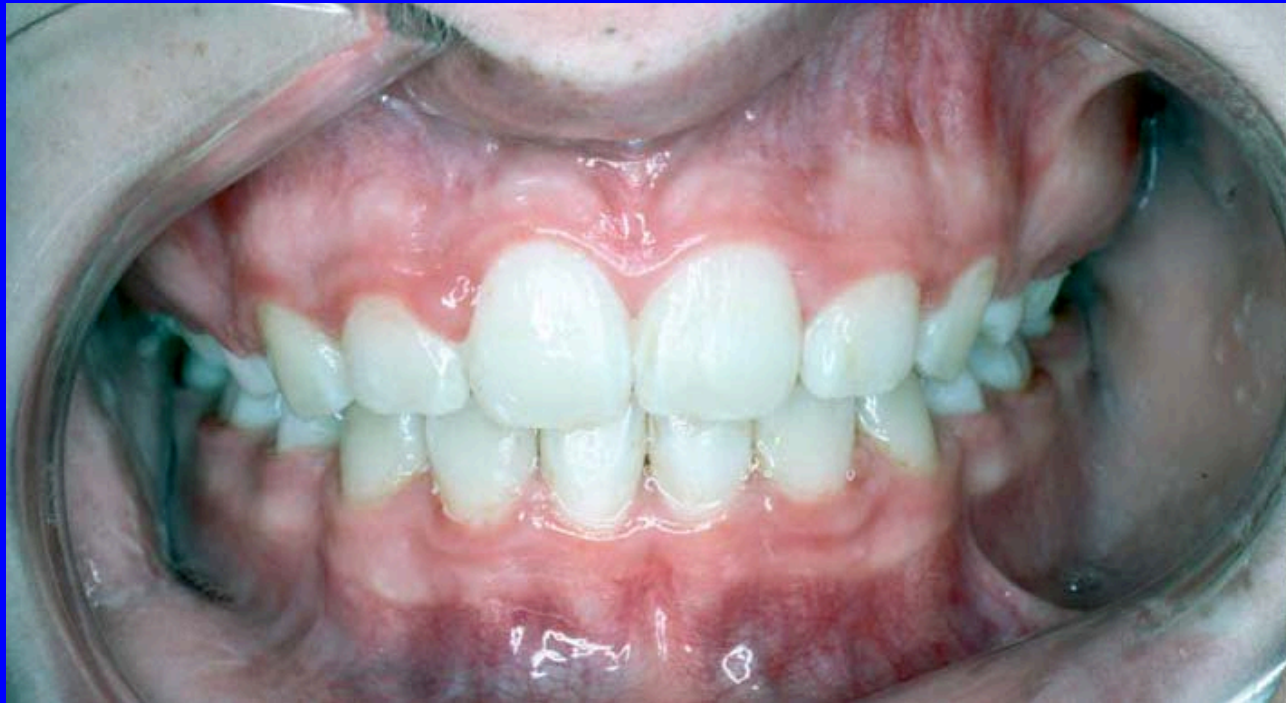



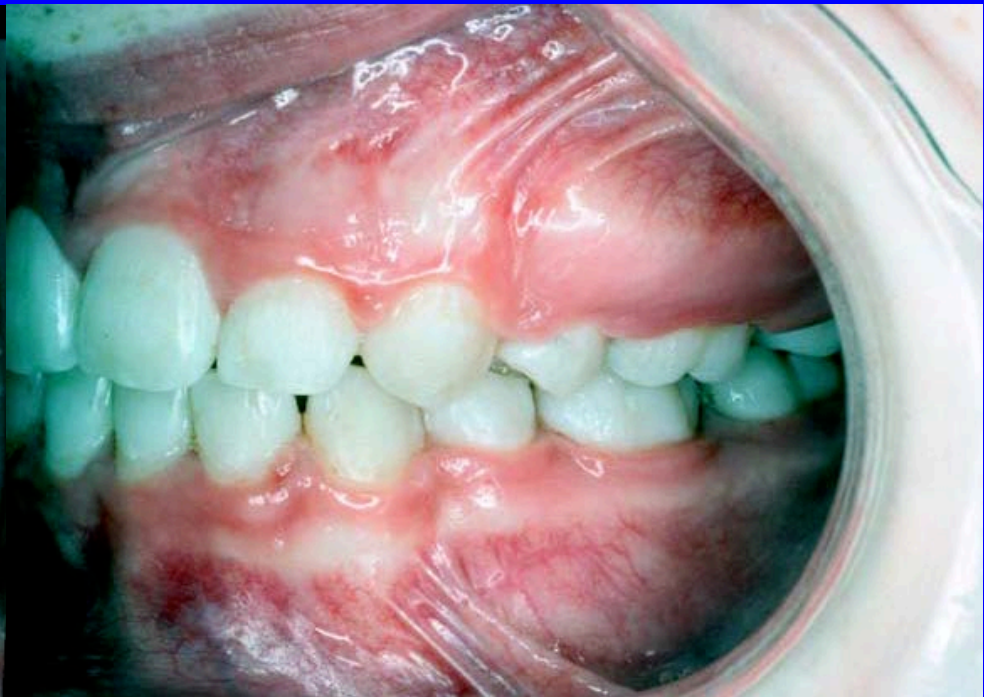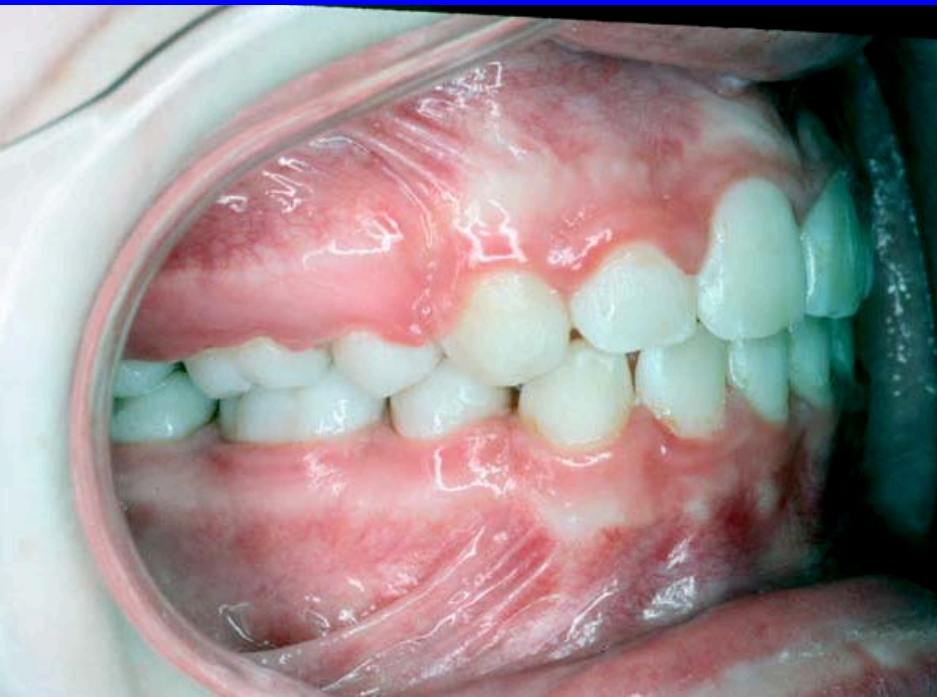M. Katen



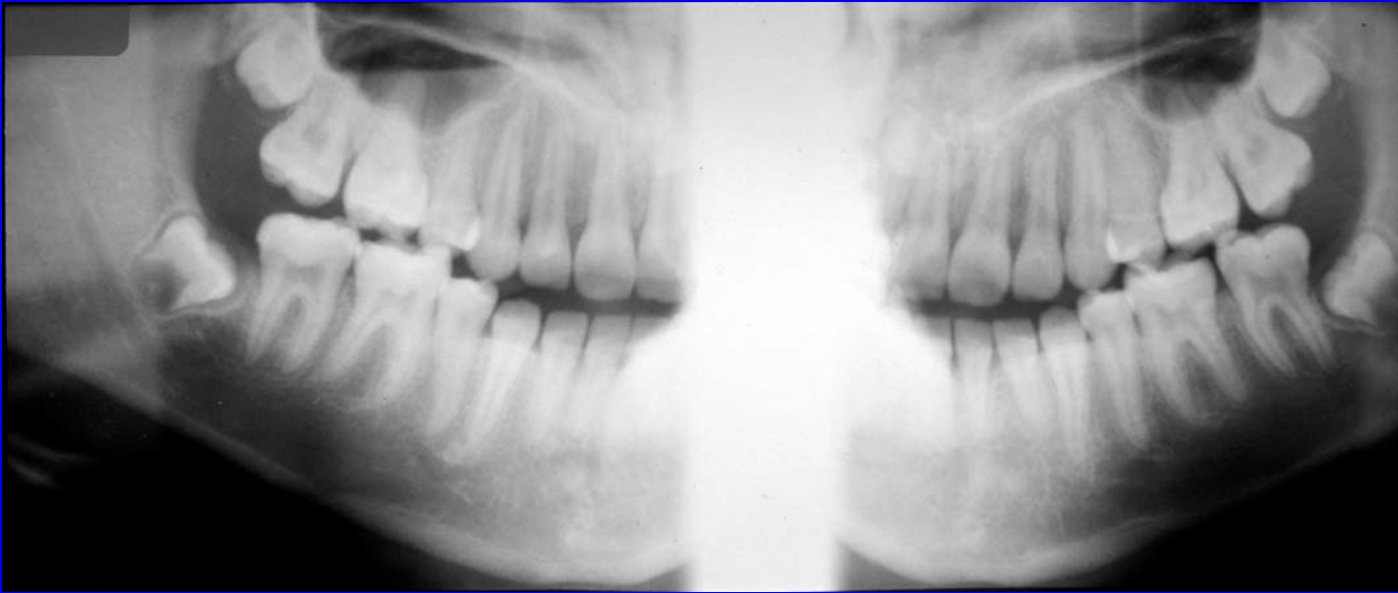
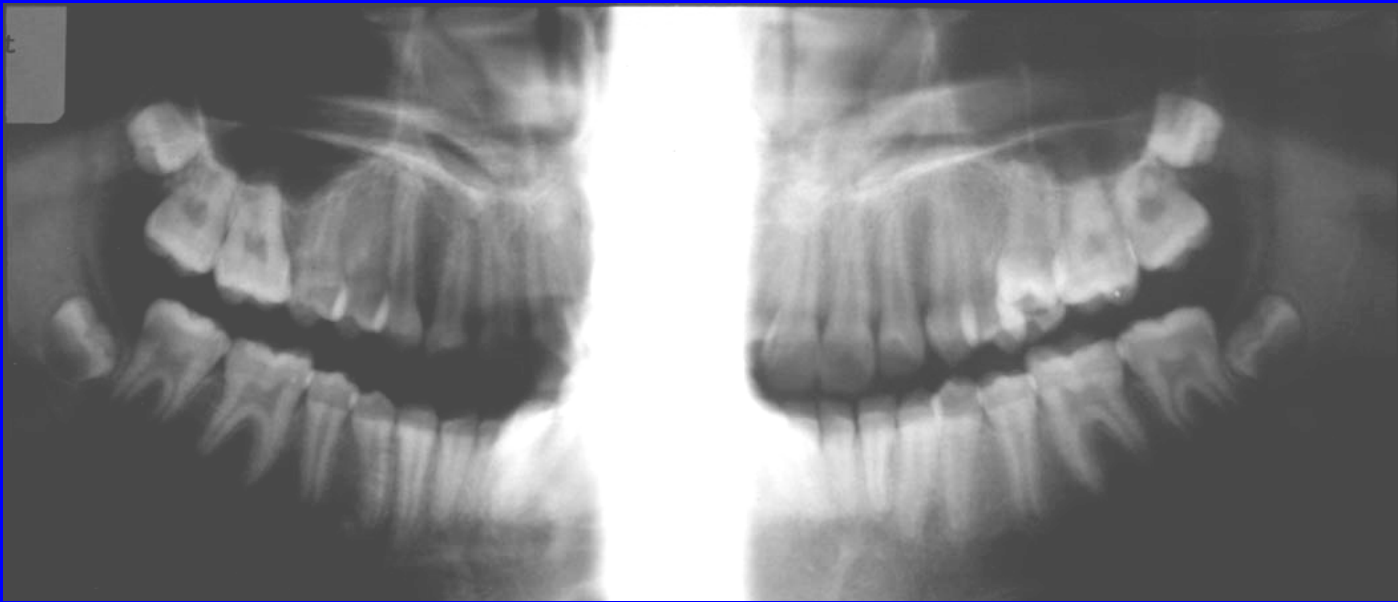
M. Katen



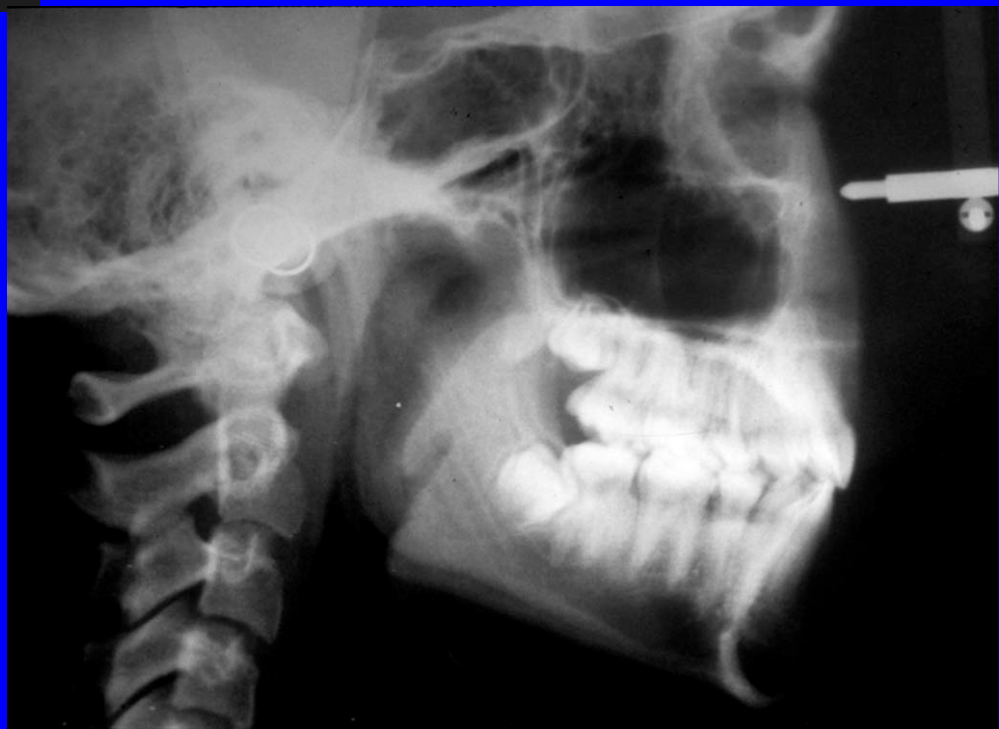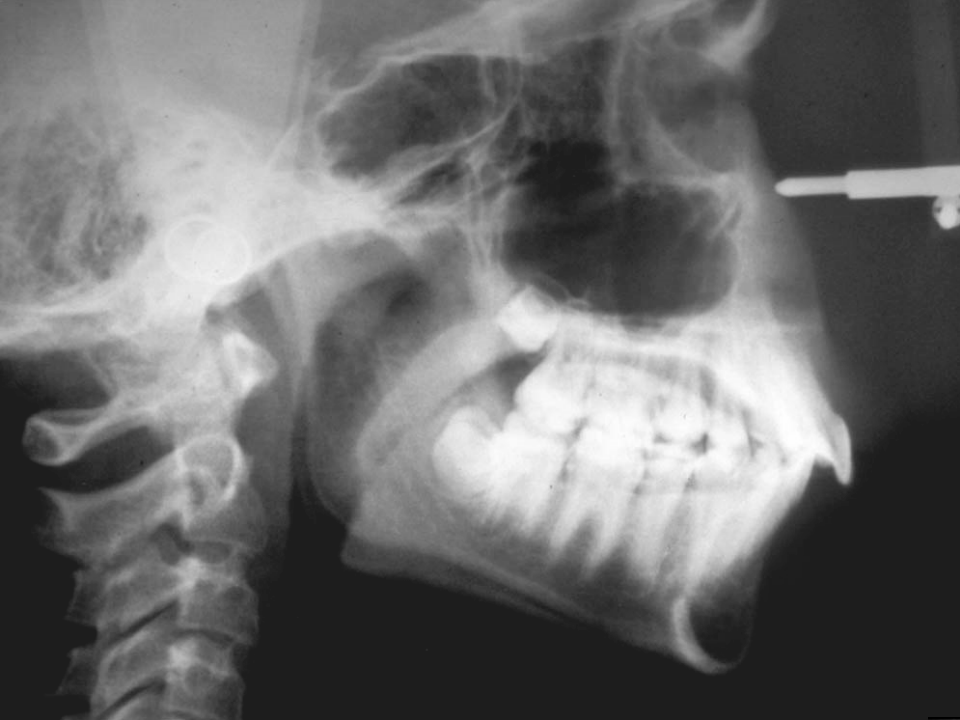M. Katen



M. Katen



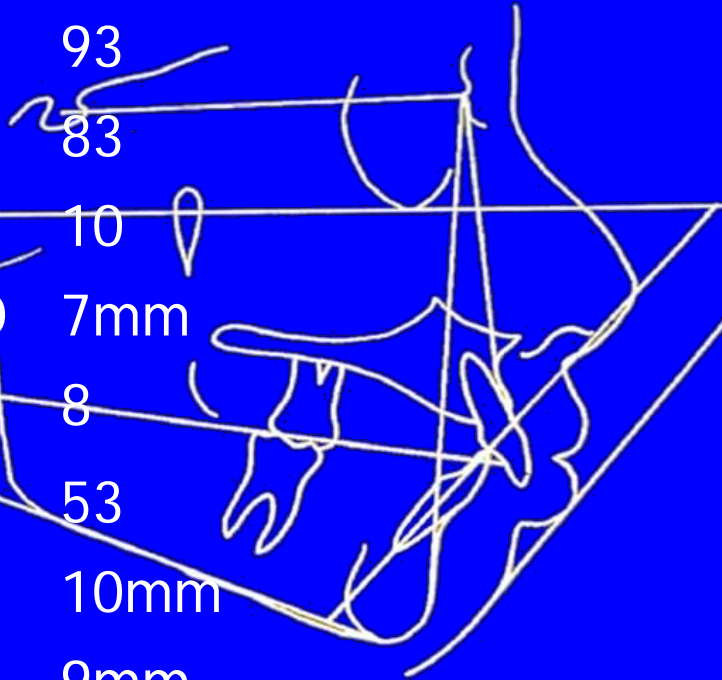
M. Katen



M. Katen

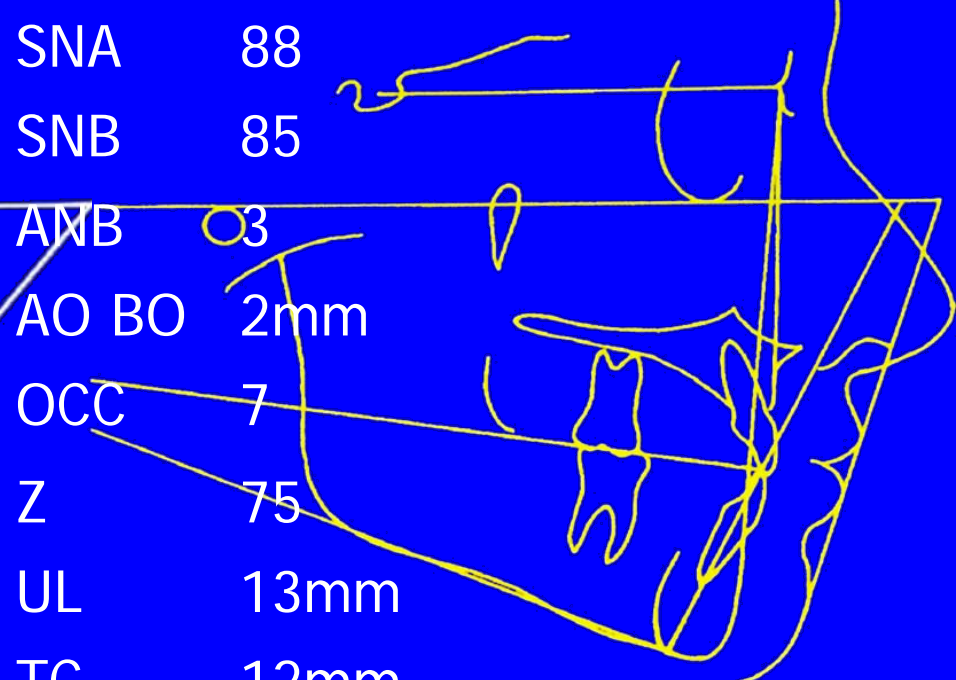
M. Katen Pretreatment

FMIA	50
FMA	25
IMPA	105
SNA	93
SNB	83
ANB	10
AO BO	7mm
OCC	8
Z	53
UL	10mm
TC	9mm
PFH	44mm
AFH	58mm




M. Katen Posttreatment

FMIA	66
FMA	23
IMPA	91
SNA	88
SNB	85
ANB	3
AO BO	2mm
OCC	7
Z	75
UL	13mm
TC	12mm
PFH	52mm
AFH	63mm

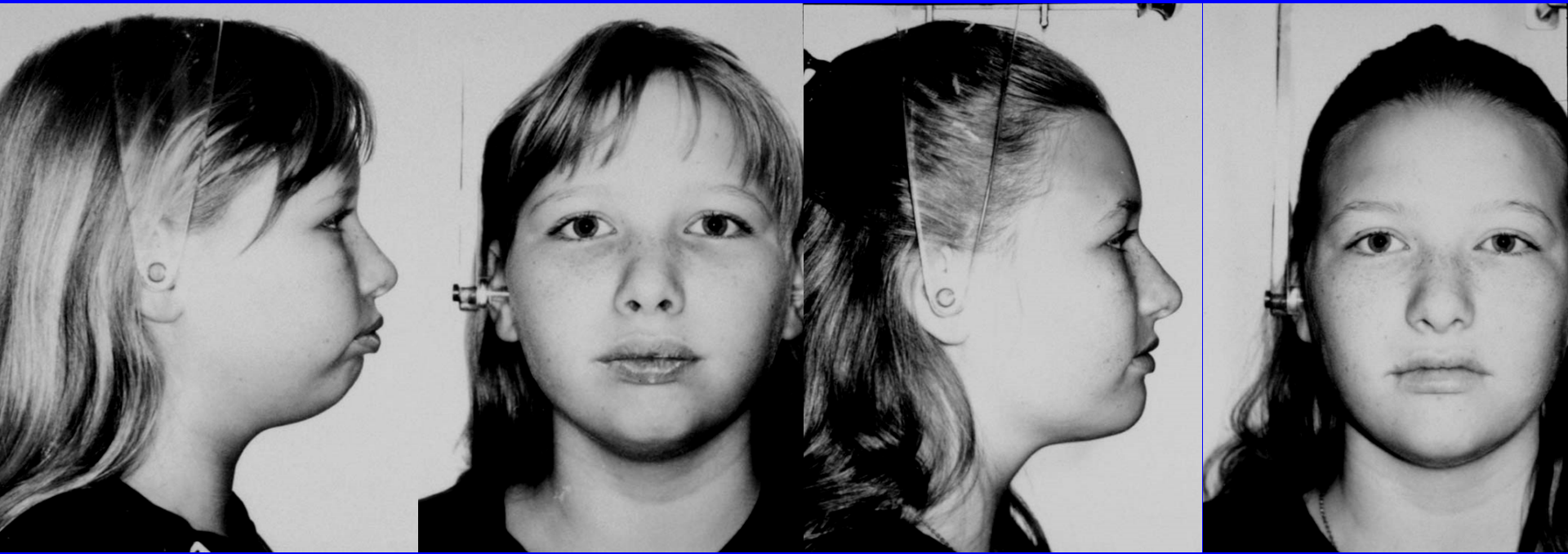

M. Katen



Pretreatment ———

Posttreatment - - - - -



M. Katen



M. Katen

POSTTREATMENT:

1. Facial esthetics has been significantly improved.
2. The “gingival smile” has been corrected.
3. Due to vertical control, mandibular response, and tooth movement the occlusion has been corrected.