

American Journal of Orthodontics and Oral Surgery

(All rights reserved)

VOL. 32

APRIL, 1946

No. 4

Original Articles

THE FRANKFORT-MANDIBULAR PLANE ANGLE IN ORTHODONTIC DIAGNOSIS, CLASSIFICATION, TREATMENT PLANNING, AND PROGNOSIS

CHARLES H. TWEED, D.D.S., TUCSON, ARIZ.

THE material presented here is the result of constant clinical observation covering a period of many years. While not unexpected, it is nevertheless gratifying to find that in the main my clinical findings, although arrived at independently, bear an extremely high degree of correlation to, and actually provide additional emphasis and concrete evidence of, the validity of the results and conclusions obtained by some of the outstanding scientific laboratory research workers in the field of orthodontics. However, many of our very able research men, after presenting their findings to us, have added to our confusion by disregarding, if not actually refuting, their own scientific investigations. I refer especially to the fact that they frequently will not or do not relate their statistical and laboratory findings to their treatment procedures. This is most unfortunate because when clinical findings and scientific research are more closely wedded, only then will many of our complex problems in orthodontics be solved—not before. Let us all remember this fact.

My clinical observations have been focused for many years on (1) the position of the mandibular incisors as related to the medullary bone of the body of the mandible—I have in the past referred to this as basal bone or dental base—and (2) the normal facial esthetics and their deviations. My observations have led me to the conviction that in all orthodontic therapy involving Class I, Class II, and bimaxillary protrusion types of malocclusion, where the growth pattern of the face is not too abnormal, the mandibular incisors must always be positioned upright on the alveolar process and over medullary bone. Furthermore, I am convinced that the normal range of variation of the inclination of the mandibular incisor teeth, as related to a plane parallel with the lower border

or base of the mandible in sagittal view, is approximately $\pm 5^\circ$, with 90° as the norm when the incisors stand at right angles to the plane parallel with the lower border or base of the mandible, i.e., the mandibular plane.

This variation in range of the normal was accepted by me as a result of my study of individuals whom I considered to possess normal occlusion. The normal as I visualize it must have, in addition to correct occlusal relationship, all five of the other qualifications as outlined in the correct interpretation of Angle's¹ definition of the line of occlusion. The possessor of all six of the fundamental requisites for normal occlusion as outlined by Angle must have a facial growth pattern normal in its entirety.

In my opinion, a thorough concept of the normal growth pattern of the child's face or any face is as important to orthodontists, if not more so, as complete mastery of the science of occlusion. Occlusion and facial esthetics, whether normal or abnormal, are so intimately associated and interdependent one upon the other that orthodontics must embrace both equally, because they cannot be dissociated. This thought was originally expressed by Angle. The man unable to correlate normal occlusion with the normal growth pattern of the face is indeed a sorry orthodontist. Let us settle the argument now and forever that it is possible to overemphasize facial esthetics in orthodontics. Normal occlusion in its correct sense is impossible without a normal facial pattern, and a normal facial pattern is none other than the ultimate in balance and harmony of facial esthetics.²

I might state here, but shall have more to say on the subject later, that the $\pm 5^\circ$ normal range of variation in the inclination of the mandibular incisors, as related to the plane formed by the lower border or base of the mandible, applies to those cases only in which growth has approximated the general normal pattern of the individual.³ It applies also to all those cases where lack of osseous growth has been general and has resulted in a slightly diminished structure of the bones of the maxilla and mandible, without markedly disturbing the directional growth of the jaws. In these cases a discrepancy often can be observed between the mesiodistal configuration of the dental arch and the tooth-bearing bones of the jaws, resulting in crowding and displacement of teeth, and giving the general appearance of too much tooth material for the available bone in which the teeth are to be accommodated. If this condition is pronounced, it becomes necessary to reduce the mesiodistal dimension of the dental arch in order to obtain both normal tooth-bony base relationship and normal facial esthetics.

The foregoing does not apply to true Class III cases or to those cases where lack of growth in the condylar growth centers has perverted the growth pattern vector from the normal downward and forward direction to too much downward and not enough forward. The lack of growth in these growth centers which causes these abnormalities is, in my opinion, more common than most of us realize. We are prone to dismiss this deformity from our problems by calling it type. Perhaps half of all our problem cases fall into this category in varying degree. In its more pronounced forms it is a condition for which the orthodontist can do little as far as facial esthetics are concerned. We shall discuss these cases more fully later.

Broadbent,⁴ Brodie,⁵ Margolis,⁶ and others have made splendid contributions on the growth and development of the head and face of the child. Brodie has demonstrated the angular constancy of the lower border or base of the mandible. By that, I mean he has shown that the plane of the lower border of the mandible when related to any fixed point, and the gonion angle when related to any constant plane, always remain virtually the same. In other words, growth is of such a nature that the planes formed by the base of the mandible at various ages from 3 months upward are always approximately parallel to one another.⁵

The parallel growth of the lower border or base of the mandible is due to its angular constancy and is quite obvious to all who have studied facial growth. Margolis⁷ deserves credit for being the first to relate the axial inclination of the central mandibular incisor with the sagittal plane tangent to the most dependent points on the lower border or base of the mandible. He has named the angle formed by the interception of the long axes of the mandibular incisors with the plane formed by the lower border of the mandible, the incisor mandibular plane angle. Margolis⁸ also calls attention to the fact that the philosophy which calls for distal movement of the denture, in certain cases of malocclusion, and the maintenance of the denture in normal relation to the rest of the head structures during orthodontic treatment, depends on the degree to which the mandibular incisors can be placed and maintained in an upright position over the medullary bone of the body of the mandible and that all of this is in accordance with evolutionary tendencies of facial growth.*

As stated by Margolis:⁸ "Up to this point (Figs. 1 to 6), it seems quite evident that there has been a reduction in the alveolar bone in man as compared with anthropoids and primitive man, so that in modern man a chin has developed. The chin is not so much a forward development of the mental eminence but rather the result of a recession of the alveolar bone. It becomes obvious then, that the mandibular incisors have been straightened upward during the process of evolution or better, during the reduction of the alveolar bone and the formation of the chin."

In spite of this conclusive evidence, I find some highly regarded scientific workers in the field of orthodontics who contend actually that it is good clinical procedure to reverse evolutionary trends in the orthodontic treatment of our patients and to make X in Fig. 9 look like IX.

As man fulfills his evolutionary destiny we find the cranium becoming increasingly larger and the face correspondingly smaller in their relative proportions to each other in the skull. While this is going on, the mandibular incisors are becoming less procumbent. Mandibular prominence is developing in direct ratio to the diminishing degree of the procumbency of the mandibular incisors. The more procumbent the mandibular incisors, the less the mandibular prominence, and, inversely, the more upright the mandibular incisors as related to the lower border of the mandible on the sagittal plane, the more pronounced the mandibular prominence, or chin.

The acceptance of the premise that in normal occlusion the mandibular incisors are always upright over medullary or basal bone certainly adds to the

*I am indebted to Dr. Margolis for the use of Figs. 1 to 13 which he has loaned me to demonstrate our views.

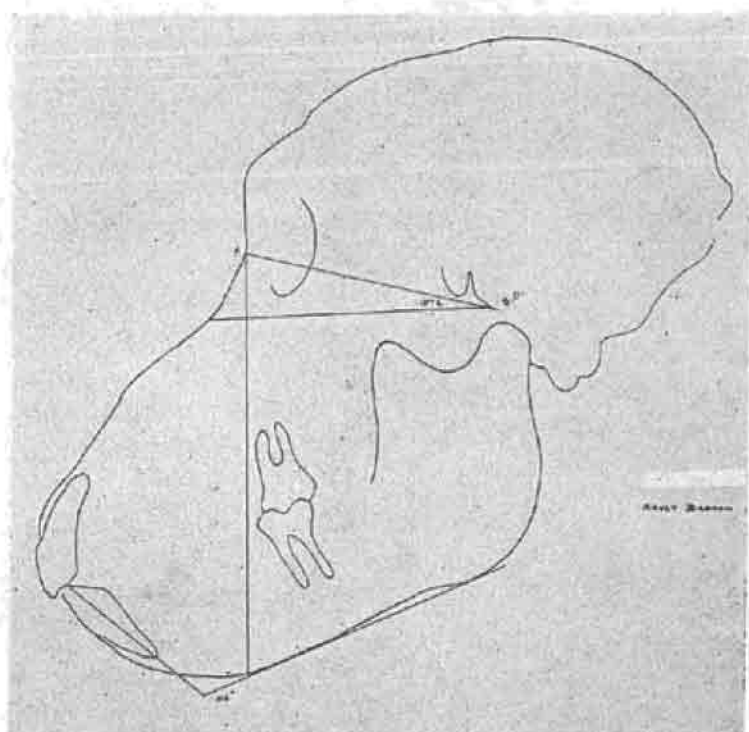


Fig. 1.—An adult baboon. Note the skull and face proportions and the high degree of prognathism.

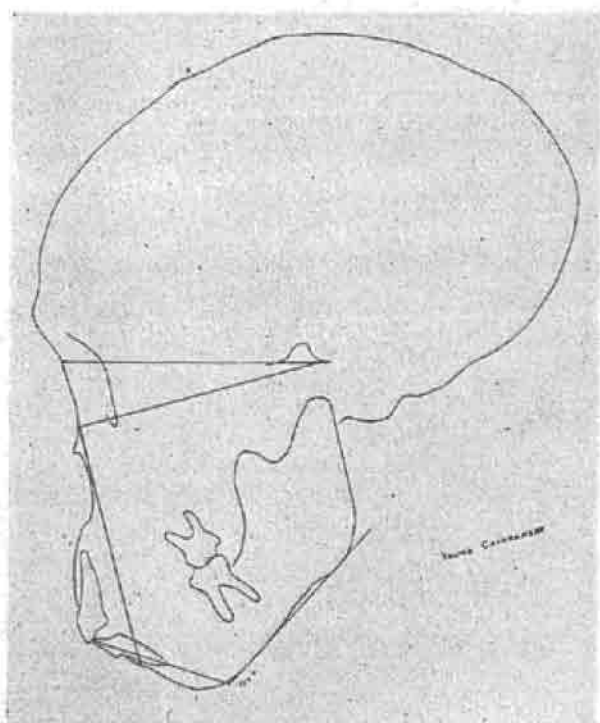


Fig. 2.—A young chimpanzee. Note similarities to Fig. 1 and compare with Figs. 3, 4, 5, and 6.

complication of orthodontic treatment. Distal en masse movement of teeth is always more difficult than mesial en masse movements. I find it most difficult to accomplish distal en masse tooth movement when there is insufficient osseous structure into which to move the teeth. Those who wear size 12 shoes and have ever tried to get their feet into size 8 shoes will know what I mean.

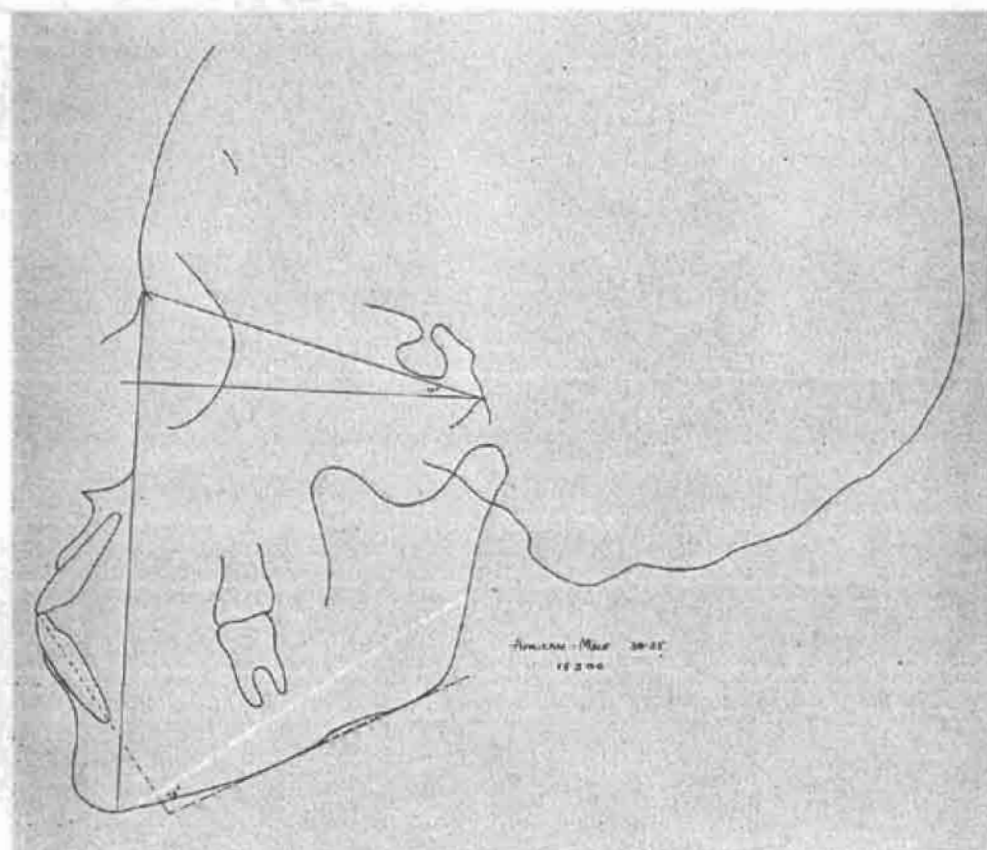


Fig. 3.—An African adult male, the tooth-bearing bones carrying the incisors, while greatly reduced in their anterior development, are still prognathous when compared to the anthropoid.

Occasionally a discrepancy can be observed between the tooth pattern and the tooth-bearing portions of the jawbones which is of such a nature that the mesiodistal configuration of the dental arch is too small in proportion to the bony base. In these cases we find spacing between the teeth. Irregularly arranged teeth and/or bimaxillary protrusion in such cases are rarely observed. The reason is that there is ample bony base to allow all the teeth to arrange themselves in accordance with the functional demands of normal denture mechanics.

When the tooth pattern-bony base discrepancy is reversed and the bone is too small in proportion to the tooth pattern, with the bony base insufficient to accommodate the teeth in normal occlusion, we find either Class I malocclusion when the facial musculature is normal, or bimaxillary protrusion if the musculature among other causes is abnormal. Irregularly arranged teeth then are frequently a manifestation of a discrepancy between tooth pattern and basal bone, as pointed out by Salzmann.⁹ Failure in growth of the basal bones occurs for various reasons, which may be apparent or obscure, and malocclusion results.

The dentition itself can remain quite stable once it reaches a state in malocclusion in which the forces originally responsible for the initiation of the malocclusion became neutralized. The proof of this statement can be found in the fact that, as a rule, the condition of malocclusion in the examples referred to in the foregoing do not become progressively worse, once a state of balance in the forces responsible for the malocclusion has been reached. The functional balance, although manifestly existing in a state of malocclusion, resists change. The irregular dentition in balance is, therefore, a far more stable condition than the same dentition treated orthodontically but forced out of balance and into protrusive relationship to the medullary portion of the bony base. Such orthodontic treatment is usually followed by "collapse."

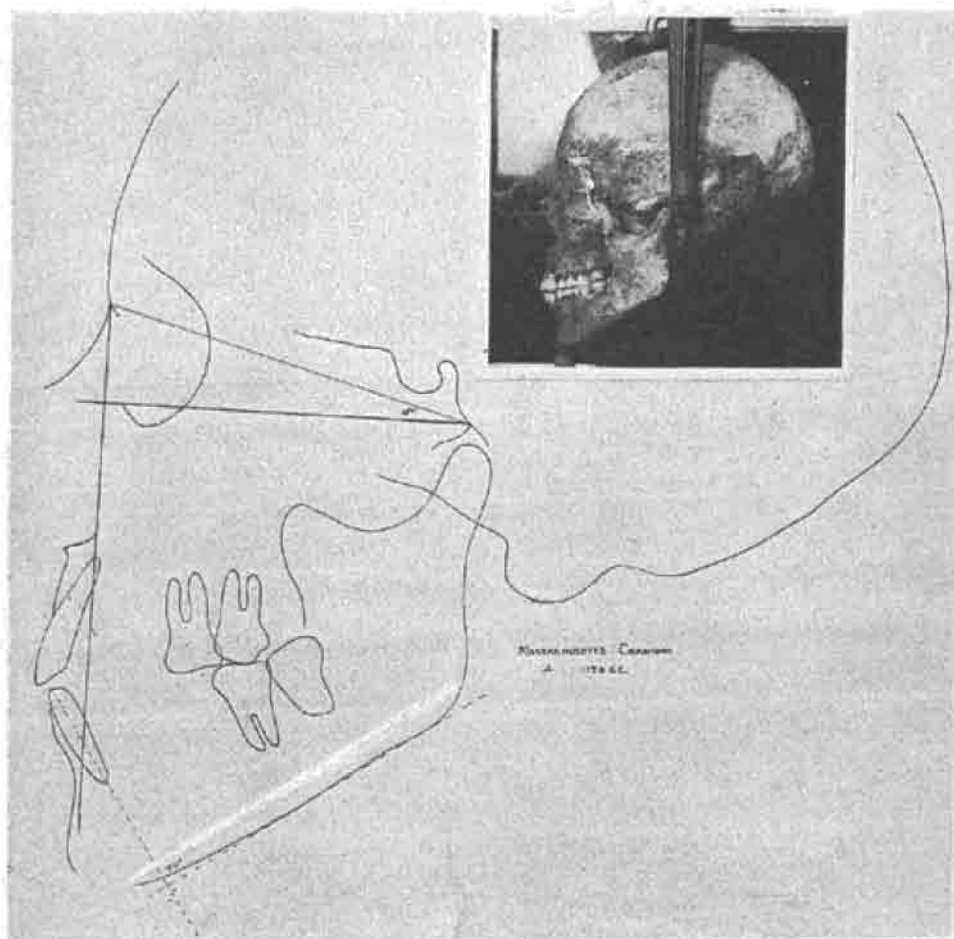


Fig. 4.—A nonprognathous Massachusetts Indian.

Facial esthetics are better with a dentition in balance, regardless of the degree of the irregularity of arrangement of the teeth, than when the irregularities are corrected at the expense of loss of dental balance. When the bony base is deficient and the dentition cannot be maintained in a state of balance by distal en masse movement of both maxillary and mandibular teeth, and in the majority of cases this is impossible, it is my practice to reduce the number of the dental units to be accommodated, rather than to create a state of imbalance with subsequent "collapse."

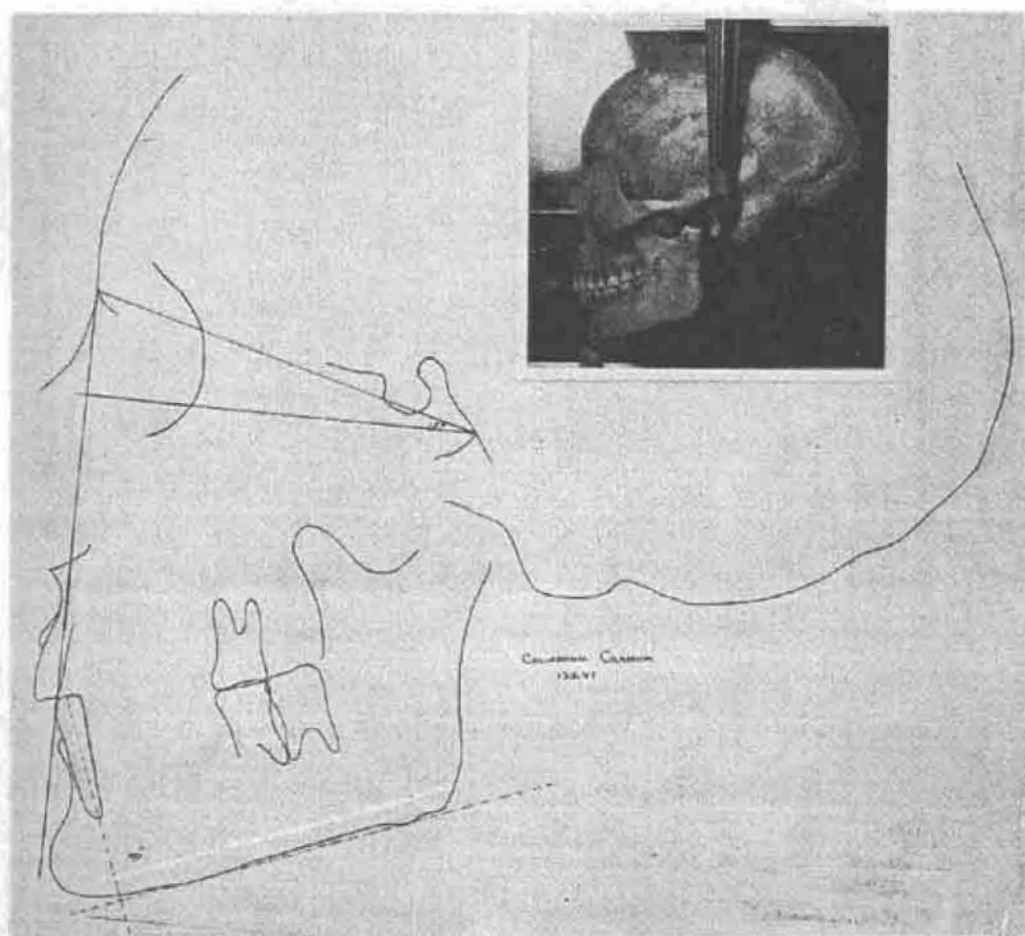


Fig. 5.—A nonprognathous California Indian with the mandible slightly more receded than in the Massachusetts skull.

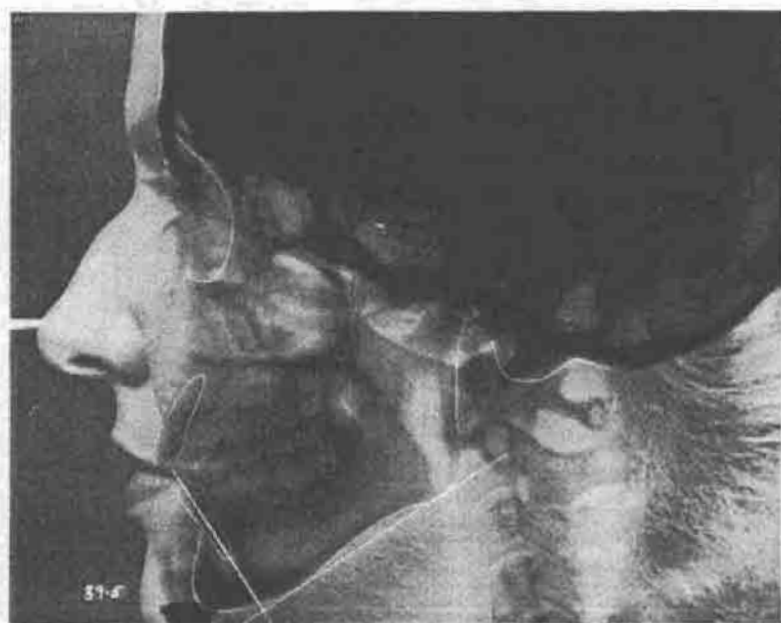


Fig. 6.—A composite x-ray photograph of a beautiful profile, certainly not prognathous, where the incisor mandibular plane angle is 89.5° , or $-3\frac{1}{2}^\circ$ in the $\pm 5^\circ$ formula.

As a general rule, teeth are irregular for the same reason that third molars are so often impacted. The reason is, I repeat, that there exists a discrepancy between tooth pattern and basal bone because of a lack of osseous growth over which the orthodontist has no control. Until we recognize and accept this fact, treatment planning will remain obscure and results of treatment will continue to be as indifferent in the future as they so frequently have been in the past.

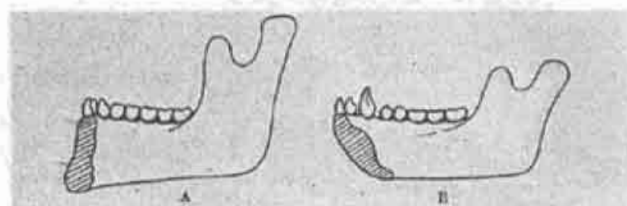
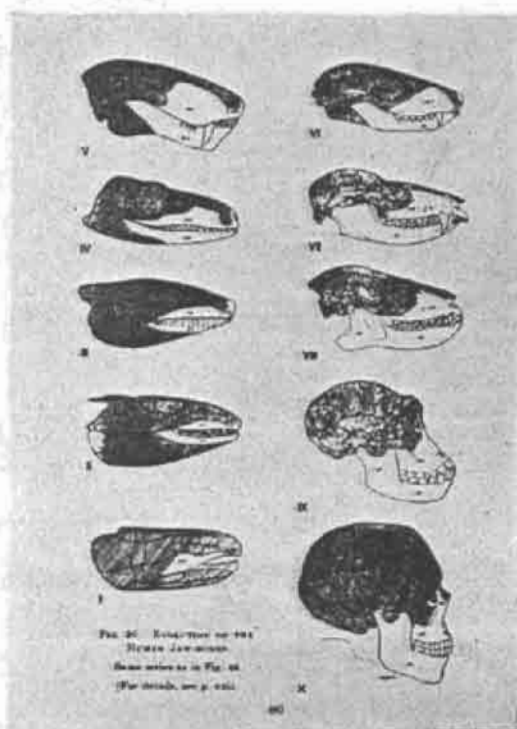



Fig. 7.—A sagittal section of the jaws of the mandible of man and monkey. Note the uprighting of the mandibular incisors in man. (From *Arboreal Man* by F. W. Jones, London, 1926, Edward Arnold & Co.)



Figs. 8 and 9.—Further examples of the reduction of the alveolar bone, the development of the chin and, last but not least, the uprighting of the mandibular incisors. (From *Our Face From Fish to Man*, by W. K. Gregory, Knickerbocker Press, G. P. Putnam's Sons, 1929.)

Let us briefly review some of the more recent research findings on tooth and jaw growth. Schour and Massler¹⁰ have demonstrated that after the third year adverse environment cannot influence the size of the teeth. They tell us that the pattern is fixed. Schour¹¹ has demonstrated the rate of bone growth during normal health. There are indications that during periods of severe childhood illness, normal growth process can be retarded or stopped, to be resumed again only with the recovery of health. It is further indicated that such losses in bone growth may never be regained by the individual at any later date.¹² Something in growth is lost forever, and the individual never attains the optimum in os-

seous growth intended by his genetic pattern. Broadbent¹³ concurs in this opinion.

When we consider that the size of the tooth pattern, after the third year, cannot be influenced by adverse health conditions, but that illness can, and does, affect osseous growth between the third and twenty-first years, it becomes quite apparent that there could be, and probably are, discrepancies between tooth pattern and the tooth-bearing bones of the jaws in the majority of cases that come to us for treatment.

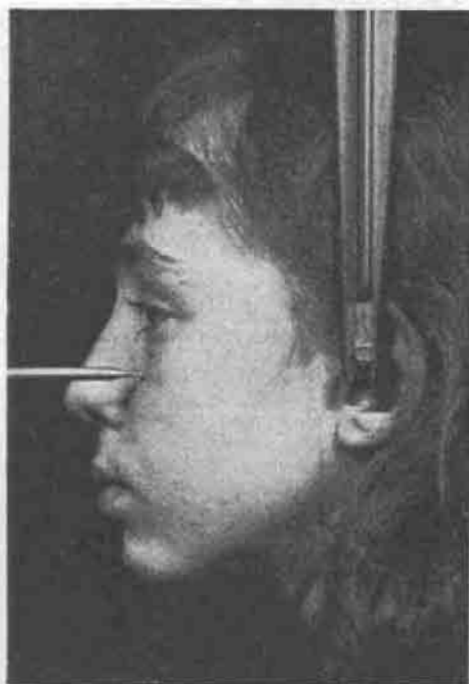

Fig. 10.

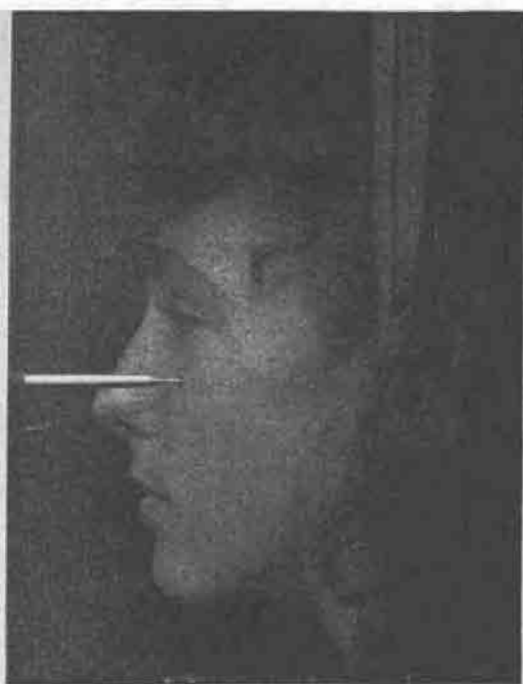

Fig. 11.

Figs. 10 and 11.—Margolis' concept of the correct application of this principle in correct orthodontic treatment. Fig. 10, Before treatment. Fig. 11, After treatment.

Then, too, there is the widely accepted possibility that man is in one of the acute transitional periods of his evolution. The cranium is increasing in size in its proportion to the face.¹⁴ The face bones are becoming smaller. The teeth are becoming less and less procumbent and all spacing between them has closed. Man is the only animal, to my knowledge, which normally does not have some spacing between the teeth. Man frequently shows failure of some of his teeth to develop. It has been pointed out that man is in a transitional period of his evolution in which a reduction in the number of his teeth is in process. When the transition is complete and the accepted formula is twenty-eight teeth, or less,¹⁵ perhaps the tooth-bone discrepancy problem will vanish, at least temporarily.

Regardless of the etiology, the fact remains that all too often the orthodontist is faced with the problem of a discrepancy between tooth pattern and medullary or basal bone. And what is even more regrettable is the fact that most orthodontists either fail to recognize the condition or refuse to do anything about it in their treatment procedures.

Brodie, in his paper, "Some Recent Observations on the Growth of the Mandible,"¹⁶ indicates that it is impossible to make tooth-bearing bones grow by means of orthodontic appliances.

Brash, working in England, Schour and his co-workers,¹⁷ and Brodie,¹⁸ in Chicago, both groups using alizarine dye injections on monkeys, gave us valuable information as to where and when growth in the mandible takes place, and where and when it does not. They found growth to be general throughout the entire body of the mandible until the eruption of the first permanent molars. Thereafter, growth was restricted to the posterior borders of the rami, the alveolar process, the border of the sigmoid notch, and the head of the condyle. The mandible grows forward by additions to the posterior borders of the rami, while some resorption of the anterior borders (now questioned by anatomists) maintains the pattern of the bone. Vertical growth is confined to additions to the alveolar process and the upward growth of the heads of the condyles against a plane that is descending. This forces the mandible downward. The condyles are apparently the growth centers that retain their activity the longest, for they must act as the compensating factors that take care of all the vertical growth processes of both mandible and maxilla.

Since generalized growth throughout the body of the mandible ceases with the eruption of the first permanent molars and is thereafter restricted to the areas mentioned above, and, as Brodie has shown us, we cannot make the body of the jawbone grow with orthodontic appliances, what are we to do when we are confronted by a patient in our dental chair, about 12 years of age, with blocked-out canines or premolars or enlocked lateral incisors. Just what should we do under these circumstances?


Let us review this picture carefully. We have our patient, aged 12 years, in the chair. He has high canines or premolars blocked out, or enlocked lateral incisors. We cannot move the teeth back because Brodie has shown that it is impossible to make basal bone grow. Brodie,¹⁸ and Schour and his co-workers¹⁷ agree that generalized growth of the body of the mandible is over by the time our patient reaches 12 years of age. Whatever growth may occur at this age is restricted to areas other than the canine or lateral incisor region. There is no chance, therefore, of moving these teeth posteriorly in the buccal segments. Shall we try to reverse evolutionary trends and "round out" the arches by positioning the incisor teeth off the medullary bone, producing a uni- or bimaxillary protrusion which is usually followed by "collapse"?

Tweed² says the mandibular incisors should always be positioned upright over the medullary bone of the jaw because all normals are that way. The growth studies of both Brodie and Broadbent substantiate Tweed's contention, even though Brodie states he does not agree.

In the August, 1944, issue of the AMERICAN JOURNAL OF ORTHODONTICS AND ORAL SURGERY, I stated the following:

For years I have contended that in normal occlusion the mandibular incisors are always positioned in an upright position on mandibular basal bone; that normals do present a variation in the axial inclination of the mandibular incisors but that this variation falls within the $\pm 5^\circ$ range, 0° being vertical and upright.

To the best of my knowledge, Dr. H. Margolis was the first to relate the mandibular incisors to the mandibular plane to create what he has termed the "Incisor Mandibular Plane Angle." He further found that in most white children with normal dentitions and nonprognathous faces, the mandibular incisors were at right angles to the mandibular plane and therefore the incisor mandibular plane was 90 degrees and the variation was less than 5 degrees either way in 90 per cent of the 300 children examined. Any variation from the right angle in this type face being toward the minus.^{3, 7}



An analysis of the incisor-mandibular plane angle based on readings of measurable cases taken from Brodie's observations on growth of face. A.J.O., p. 750, August 1940. According to Brodie, these were normal male children picked at random.

This chart represents 11 of the 20 cases selected by Brodie. The remaining 9 cases did not have the roots drawn in; but, judging from the crowns, they indicate the same range.

Note: No incisor has a greater inclination than the upper limit of the suggested range.

Fig. 12.

In the August, 1940, issue of the AMERICAN JOURNAL OF ORTHODONTICS AND ORAL SURGERY, there appeared an article by Allan G. Brodie, "Some Recent Observations on the Growth of the Face and Their Implications to the Orthodontist."¹⁹ The basis of his report was the records of twenty-one normal children who were selected at random—on the basis of excellence of roentgenograms—eleven in the three-month to seven-year range and ten in the six-month to eight-year range. Each series of roentgenograms consisted of fourteen sets of headplates taken quarterly during the first year of life, semiannually from 1 to 5 years, and annually from then on. All were males. On page 750, Fig. 8, of the article by Brodie mentioned here, are shown the growth patterns of these children. In nine of these cases in that series only the crowns were traced and not the roots, so the incisor mandibular plane angle could not be measured. In the other eleven instances the incisor mandibular plane angles are as follows:

- In one case the angle is 92 degrees.
- In six cases the angle is 90 degrees.
- In one case the angle is 84 degrees.
- In one case the angle is 87 degrees.
- In one case the angle is 85 degrees.
- In one case the angle is 83.5 degrees.

The angular variation of the mandibular incisors with relation to the lower border of the mandible is 8.5° in this group of normals.

The average for these eleven cases is an incisor mandibular plane angle of 88.3° , which is vertical or upright and well within the range of the $\pm 5^\circ$ formula. In fact, it is -1.8° .

In the *Angle Orthodontist*, October, 1941, page 239, Fig. 11, in B. Holly Broadbent's paper, "Ontogenic Development of Occlusion," there appears an illustration summarizing the study of normal dentofacial developmental growth from the Bolton Study records of 3,500 white Cleveland children.²⁰ This illustration reveals the following facts:

1. The composite, representing the children in the $3\frac{1}{2}$ -year bracket shows the incisor mandibular plane angle to be 90° .
2. The composite, representing the children in the 7-year bracket, shows the incisor mandibular plane angle to be 81° .
3. The composite, representing the children in the 14-year bracket (the ones we are most interested in), shows the incisor mandibular plane angle to be 87.5° .
4. The composite, representing the adults, shows the incisor mandibular plane angle to be 91.5° .

The average for these 3,500 cases is an incisor mandibular plane angle of 87.9° , which is within 0.8° of the average for the normals reported by Brodie. Again, an incisor mandibular plane angle of 87.9° is upright and nearly vertical; being so, it is obvious that in normal occlusion the mandibular incisors are upright on mandibular basal or medullary bone of the body of the mandible, as I originally pointed out. The findings of Brodie and Broadbent were arrived at independently by them. They certainly did not go out to "prove" anything. They engaged and are engaging in research in order to report the facts as they find them. It is indeed gratifying that their findings substantiate my clinical observations and conclusions, regardless of the fact that the men themselves did not correlate their findings to my clinical procedure as shown in the foregoing and in the facts presented below.

Let us come back to our patient: Our little friend is still in the chair waiting. Our patient, or at least his mother, is interested only in changing her child's "funny face" for a better appearing one and his "crooked teeth" for "straight ones" that will remain "straight." His buccal teeth cannot be moved distally according to Brodie, Schour, and many others. The mandibular incisors must not be displaced forward into protrusion, according to Tweed and many others since, who are at long last enjoying the practice of orthodontics.

There is much work to be done if we ever hope to clear up this confusion of thought and iron out correct treatment procedures. Clinical observation and research and scientific research and correlation must become brothers. Advancement in orthodontics, as in other fields of medical science, is equally dependent on both.

The import of Broadbent's contribution to orthodontics has not been fully appreciated by many of us. The advent of cephalometrics was indeed a happy day for orthodontics. The tracings of the growth studies of Broadbent, Margolis,

Brodie, Higley, Humphrey, and many others, are most enlightening. These authors point out planes, angles, curves, trends, etc. It is unfortunate that many of us look only where they point their fingers, no further, and say, "Wonderful." Most of us have again missed the boat just as we did by interpreting incorrectly Angle's definition of the "Line of Occlusion." No man, including Broadbent, I feel, has ever completely digested the information made available from his tracings. Most of us have been guilty of glancing at them only, and passing them by.

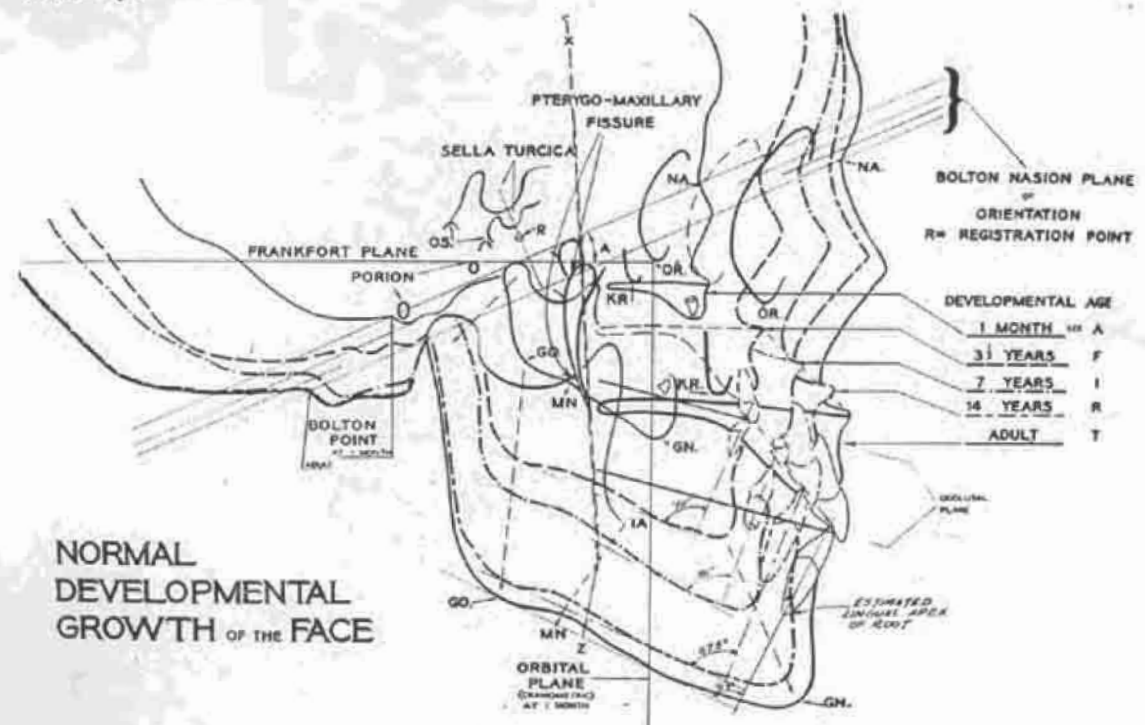


Fig. 13.—Chart of normal dentofacial developmental growth from the Bolton Study records. (Broadbent, B. Holly: *Ontogenic Development of Occlusion, The Angle Orthodontist* 11: 239, 1941.) (Incisor mandibular plane angle drawn in by Herbert I. Margolis.)

A recent review of these tracings, with a closer study of lateral photographs of skulls and heads of living subjects oriented on the Frankfort plane, has added further corroborative evidence of the validity of certain facts which I had arrived at by clinical study and investigation. I shall endeavor to present here a practical method of value in diagnosis, classification, treatment planning, and prognosis, which can be used in the everyday practice of orthodontics without additional expensive equipment. The procedure to be presented here employs the Frankfort plane and the plane tangent to the most dependent points on the lower border or base of the body of the mandible, i.e., the Frankfort and mandibular planes, which when extended into space meet and form the Frankfort-mandibular plane angle.

A study of the tracings made from sagittal head x-rays of normal growing children reveals certain trends that are not too difficult to understand. When one becomes familiar with the normal growth pattern, it is quite simple to compare it with the growth pattern of the abnormal and determine approximately the extent of the deviation from the normal. However, this information has in

the past been regarded as being of academic interest only. It need no longer remain so, because, as we shall show here, it has a deep and vital significance in our daily practice.

As shown in the foregoing, Brodie¹⁹ and others have demonstrated that once the growth pattern of the facial bones is established, whether normal or abnormal, it is virtually constant and resists change. For instance, in those cases where there has been injury to the condylar growth centers that temporarily retards growth in these centers, we find short rami, and growth is diverted more downward and less forward than in the normal growth vector, which is downward and forward. This loss in the normal, proportional bone pattern is never regained by the individual by future growth spurts. This statement is supported by the fact that the parallelism of the lower borders of the mandible continues in the abnormal direction during the subsequent growth of these individuals. It is obvious to all of us that such a case is to be avoided because there is little other than correction of occlusal relationships that the orthodontist can do for these patients. Yes, we all recognize that, but I wonder how many of us realize that a great many of our problem cases are but variations of this same condition. And, because we fail to detect a faulty growth pattern, we become befuddled. Were we more observant, we would recognize these cases at once and realize that, because of the abnormal growth pattern, we shall never be able to attain all of our orthodontic objectives, regardless of how we treat the case.

A classification of prognosis* that will pick out these cases should be of great value to all of us. My purpose is to make a start in that direction, with the hope that others will consider the problem worthy of further study.

In using this diagnostic method, we can employ Salzman's Maxillator²¹ and take our measurements directly on the patient, or we may employ a sagittal head x-ray or profile photograph.†

When sagittal x-rays or photographs are used, the Frankfort plane is extended posteriorly through the back of the head. The plane formed by the lower border of the mandible is likewise extended posteriorly until it intercepts the Frankfort plane. The degree of the angle formed by the intercepting of these two planes will determine the location of the point of interception of these planes, which is somewhere distal to the auditory meatus. We shall refer to this angle as the Frankfort-mandibular plane angle when the Frankfort plane is used; the Bolton-mandibular plane angle when the Bolton plane is used. We shall use the Frankfort plane, because for our purposes it is more practical.

If the Frankfort-mandibular plane angle (these figures are at present approximations) is between 16° and 28°, the growth vector has been downward and forward to a degree which is normal. These cases will frequently have

*By "prognosis" I mean the attaining of, or as nearly as possible the attaining of, all four orthodontic objectives which, I feel, all orthodontists should strive for. These are:

1. The best possible in facial esthetics.
2. Permanency of end result.
3. An efficient masticating apparatus.
4. Longevity of the dentition.

†Add 5 to 7 degrees to the above figures when measuring on sagittal head x-rays.

normal occlusion or an osseous growth pattern of but slight deviation from normal, even though the malocclusion is of a severe nature. The orthodontist can be reasonably certain of a permanent result with excellent facial esthetics if he will reduce the tooth pattern so that it is in keeping with the osseous bulk

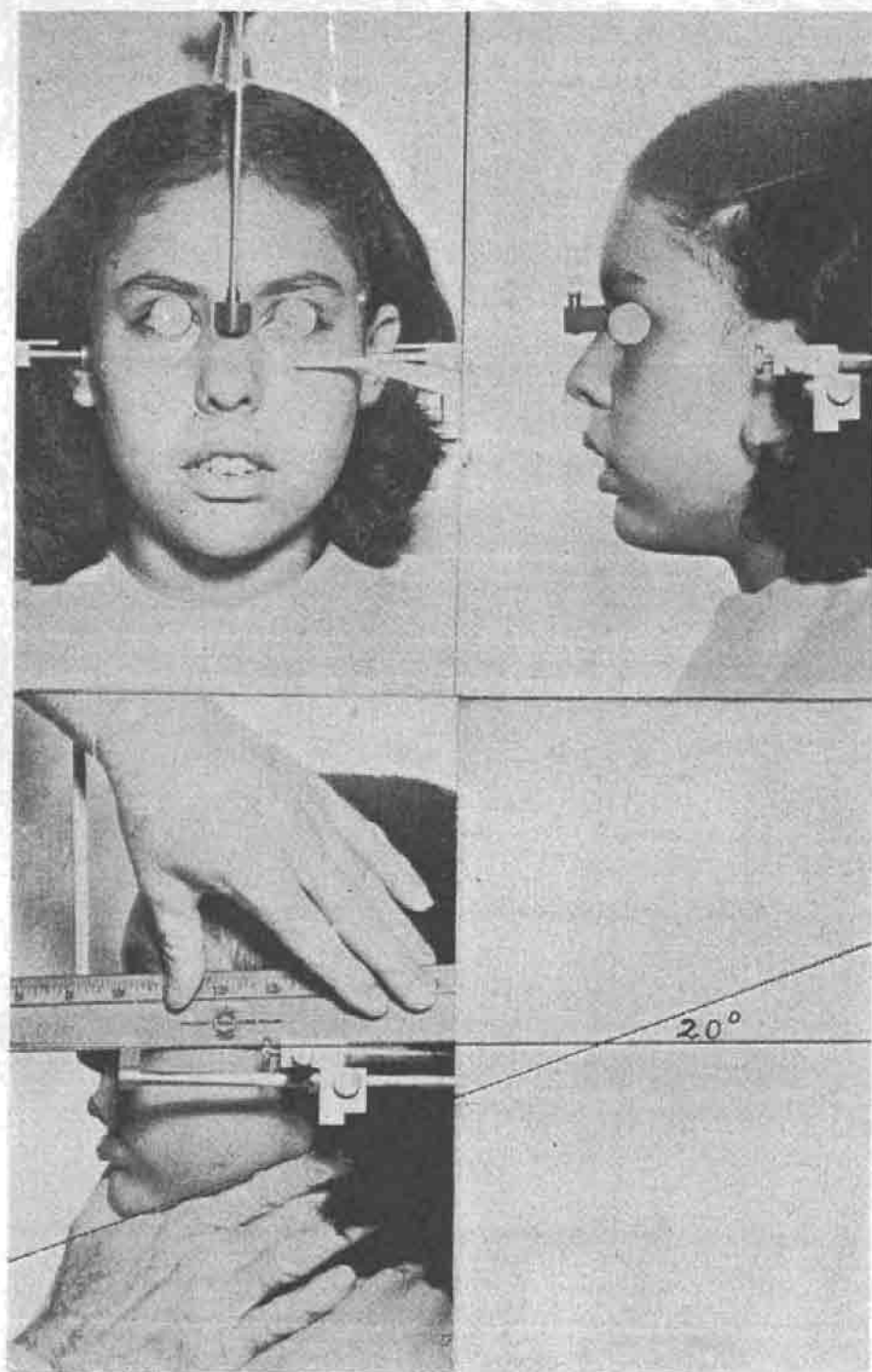


Fig. 14.—An excellent face pattern in which the Frankfort-mandibular plane angle is 20° . The case is a Class II malocclusion complicated by a discrepancy between tooth pattern and basal bone. If this discrepancy is corrected, there is no reason why all four of the orthodontic objectives cannot be attained. Prognosis is excellent.

if and when such procedure is indicated. The Frankfort and mandibular planes will intercept each other somewhere behind the head. The distance of their interception posteriorly from trignon will vary from $3\frac{1}{2}$ inches to 8 inches or more, depending on the degree of the Frankfort-mandibular plane angle. The $\pm 5^\circ$ variation of the mandibular incisors will apply to all of these cases. However,

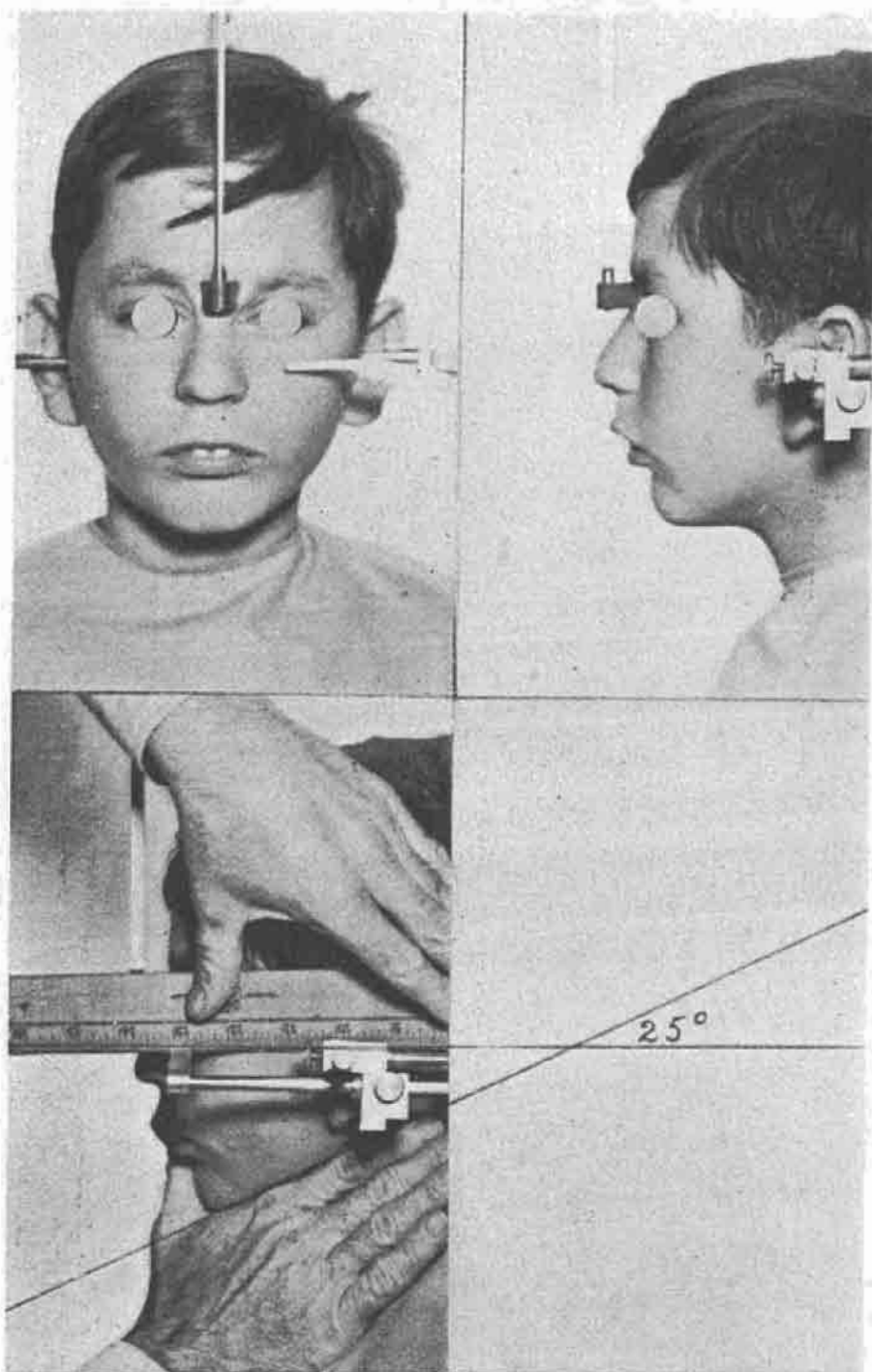


Fig. 15.—Another favorable growth pattern in which the Frankfort-mandibular plane angle is 25° . The case is a Class II, Division 1 malocclusion, complicated by a discrepancy between tooth pattern and basal bone, which requires the removal of all four first premolars. Prognosis is very good.

the $+5^\circ$ will apply more to those cases whose Frankfort-mandibular plane angle is nearest the 16° extreme, and 0° to those cases that fall around the Frankfort-mandibular plane angle of approximately 22° . When the Frankfort-mandibular plane angles range from 22° to 28° , the correct positions of the mandibular

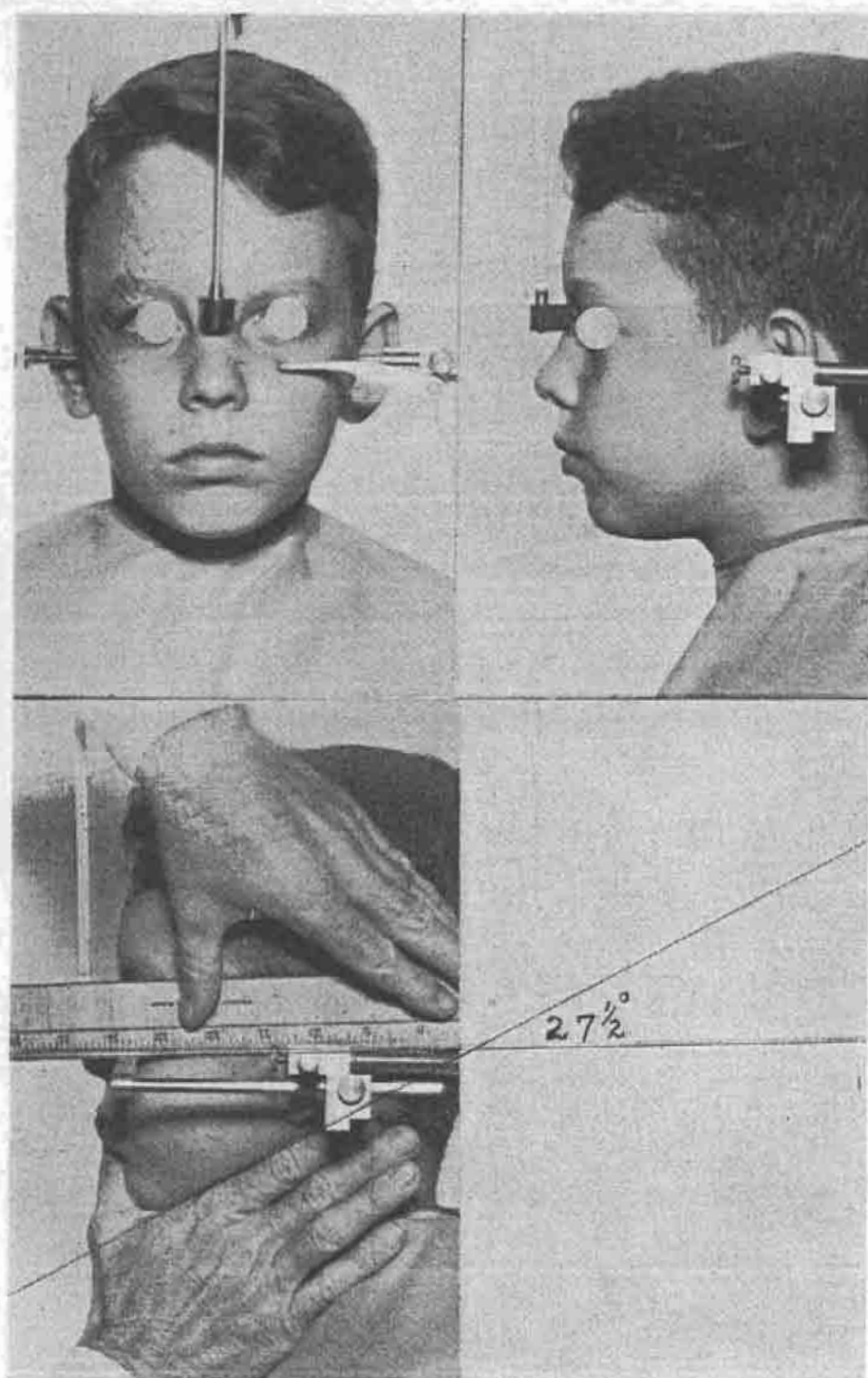


Fig. 16.—Another favorable growth pattern. The Frankfort-mandibular plane angle is $27\frac{1}{2}^\circ$. The case is a Class II, Division 1 malocclusion in which there exists a discrepancy between tooth pattern and basal bone requiring the extraction of all four first premolars. Prognosis is good.

incisors will vary from 0° when the Frankfort-mandibular plane angle is 22° , to -5° when that angle increases to 28° . My opinion is that about 60 per cent of all malocclusions will fall within a 16° to 28° range of the Frankfort-mandibular plane angle when measurements are taken from profile photographs. More than half of these cases will require reduction of tooth pattern if proportions approximating the normal are to be realized.

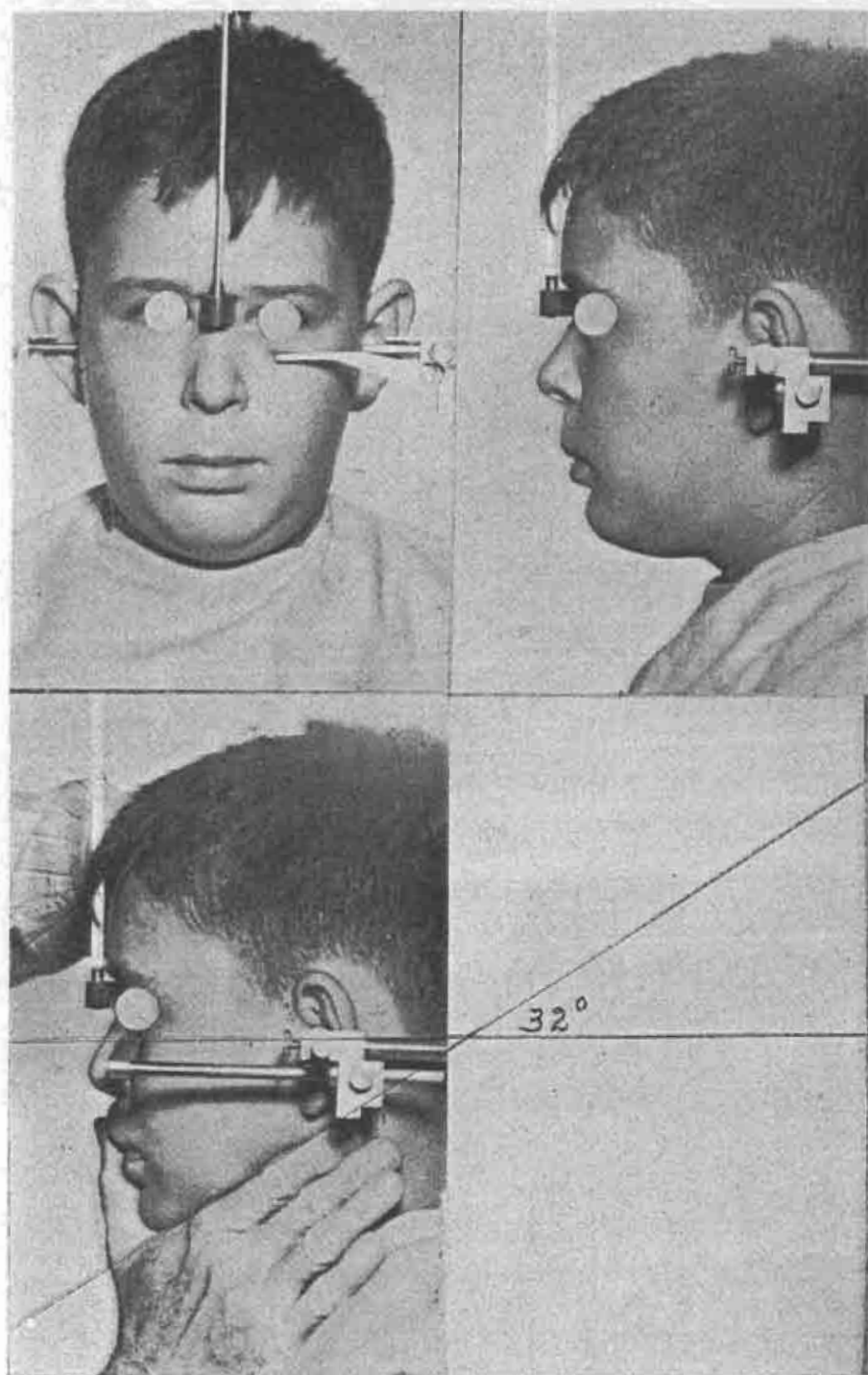


Fig. 17.—Here the directional growth of the face is only fair. The Frankfort-mandibular plane angle is 32° . A nonextraction case. Prognosis is fair.

When the Frankfort-mandibular plane angle is from 28° to 35° (measurements taken from photographs), the growth vector is not so favorable. Cases in the angular classification that fall nearest the 28° extreme can be, in most instances, satisfactorily treated with favorable changes in both facial esthetics and occlusal relationship. The growth vector is not too abnormal and the $\pm 5^{\circ}$

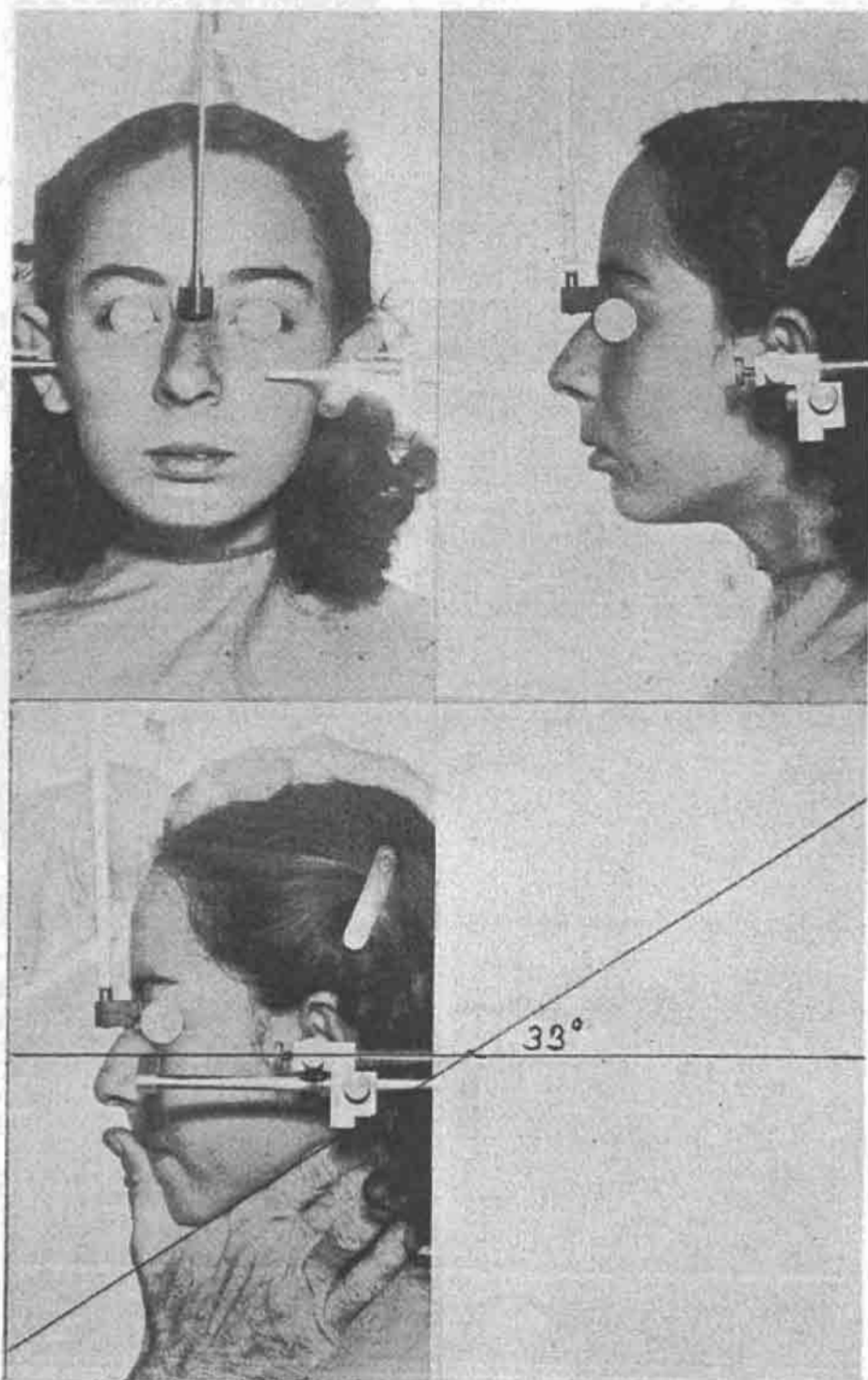


Fig. 18.—The face pattern is not too favorable. The Frankfort-mandibular plane angle is 33° . The case is a Class II, Division I malocclusion, complicated by a discrepancy between tooth pattern and basal bone requiring the extraction of all four first premolars. Prognosis is fair.

formula can be applied, but it will be found that the inclination of the mandibular incisors must fall near the -5° extreme. Prognosis is good. A larger percentage of these cases will require extraction of teeth, as procumbent tendencies are more pronounced. When the Frankfort-mandibular plane angle approaches

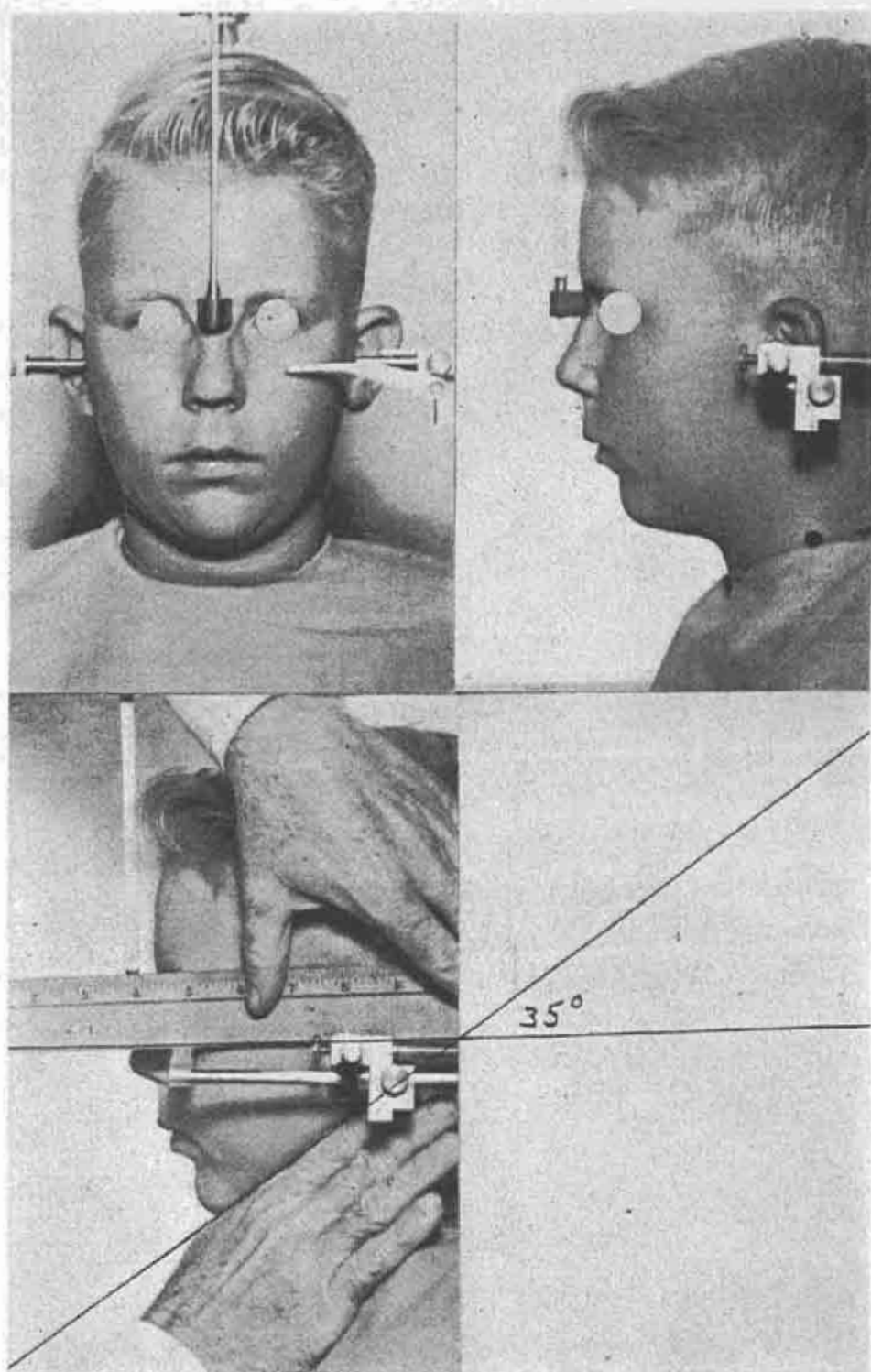


Fig. 19.—This case presents a Frankfort-mandibular plane angle of 35° , which would indicate that the directional growth of the face pattern is bad. The case is complicated by a discrepancy between tooth pattern and basal bone requiring the removal of all four first premolars. From the standpoint of obtaining all four orthodontic objectives, prognosis is bad.

nearer to the 35° extreme, prognosis is only fair, and favorable prognosis diminishes in direct ratio to the increase in degree of the Frankfort-mandibular plane angle. The $\pm 5^\circ$ formula cannot be applied to these cases because the mandibular incisors must be positioned from -5° to -10° .

When the Frankfort-mandibular plane angle is much greater than 35° , few of these cases can be appreciably benefited by orthodontic treatment. Prognosis is bad. Virtually all cases showing a Frankfort-mandibular plane angle of from 28° to 35° will require removal of teeth. When the Frankfort-mandibular plane angle is from 30° upward, the $\pm 5^\circ$ formula will not apply.

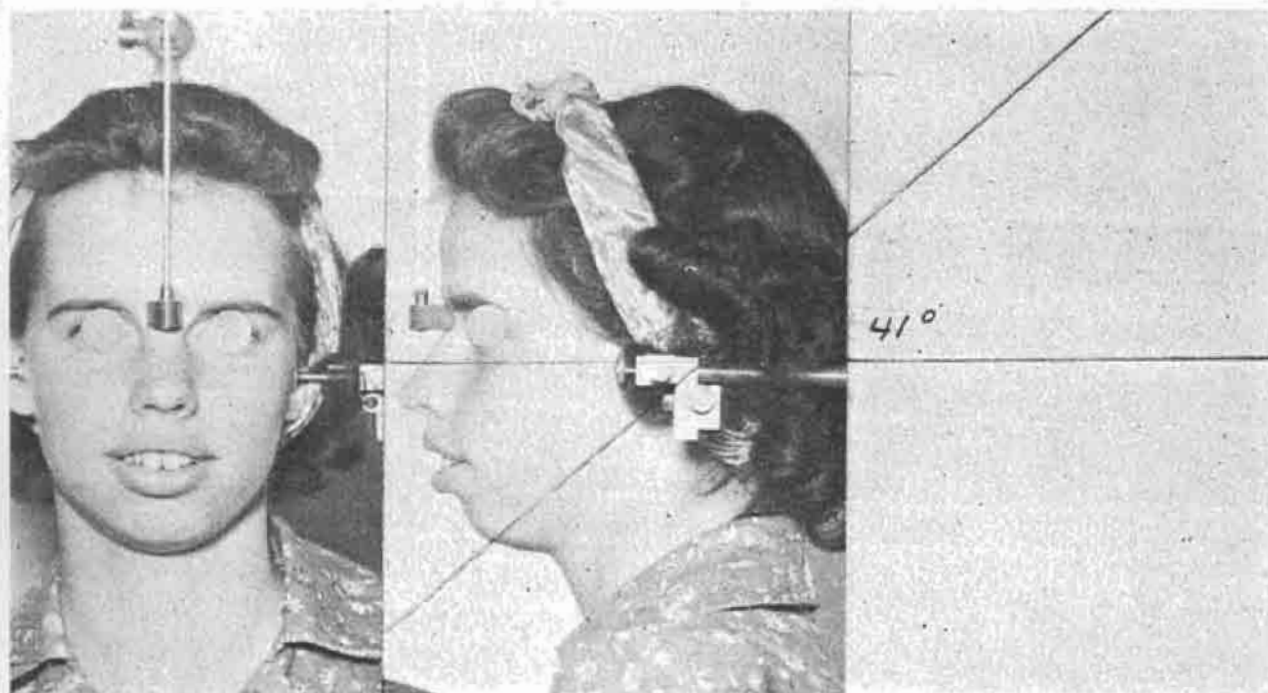


Fig. 20.—Here the directional growth of the face pattern is chaotic. The Frankfort-mandibular plane angle is approximately 41° and prognosis is virtually nil. The extraction of teeth in this instance would perhaps complicate matters rather than enhance facial esthetics.

As the Frankfort-mandibular plane angle increases from 35° upward, favorable prognosis is nil. In some instances the removal of teeth in this range (when the Frankfort-mandibular plane angle is 40° or more) will complicate matters and detract from, rather than enhance, facial esthetics. The growth pattern in this category is so perverted that the vector of growth is virtually downward and but slightly forward, rather than downward and forward. As the Frankfort-mandibular plane angle increases in degree, it approaches the tragion point more closely.

To Summarize.—

1. In cases that fall within the Frankfort-mandibular plane angle range of 16° to 28° , the prognosis varies from excellent for those nearest the 16° extreme to good for those cases nearest the 28° extreme.

2. In cases that fall within the Frankfort-mandibular plane angle range of 28° to 32° , the prognosis will vary from good at 28° to fair at the 32° extreme.

3. In cases that fall within the Frankfort-mandibular plane angle range of 32° to 35° , the prognosis is fair at 32° and not favorable at 35° .

4. In cases that fall within the Frankfort-mandibular plane angle range of 35° upward, prognosis is not favorable at 35° and virtually nil at extremes such as 45° to 55° .

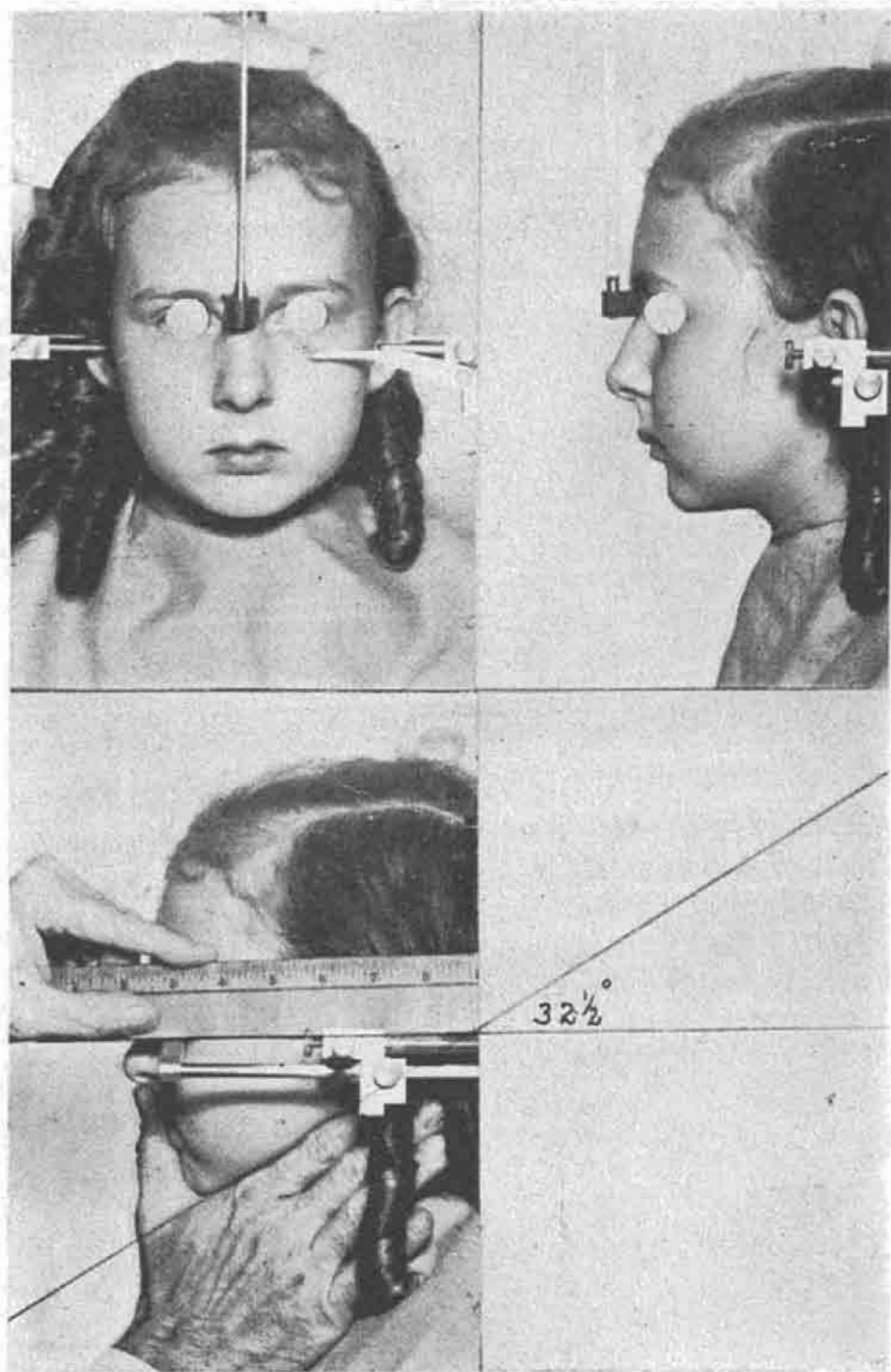


Fig. 21.—Method of obtaining Frankfort-mandibular plane angle.

Procedures for Obtaining the Frankfort-Mandibular Plane Angle.—In actual practice on the patient, the Frankfort-mandibular plane angle can be obtained by means of the Salzmann Maxillator or by the following method:

The fingers and thumb of the right hand are extended, palm down. The fingers are kept together while the thumb extends from the palm of the hand at approximately a 90-degree angle from the fingers. The thumb is placed in the area at subnasion on the patient, and gnathion, or the chin, will rest in the angle of the hand formed by the thumb and palm (Fig. 21). A slight upward pressure of the hand with the fingers extended under the lower border of the mandible to gonion will clearly outline the lower border. With the left hand place a rule lightly against the patient's face, connecting orbitale and tragon. Have the rule extend posteriorly beyond tragon at least 6 or 8 inches. The assistant now places another rule along the line formed by the palm and upper border of the index finger with the lower border of the mandible. The Frankfort-mandibular plane angle will be formed at the intersection of the two rules.

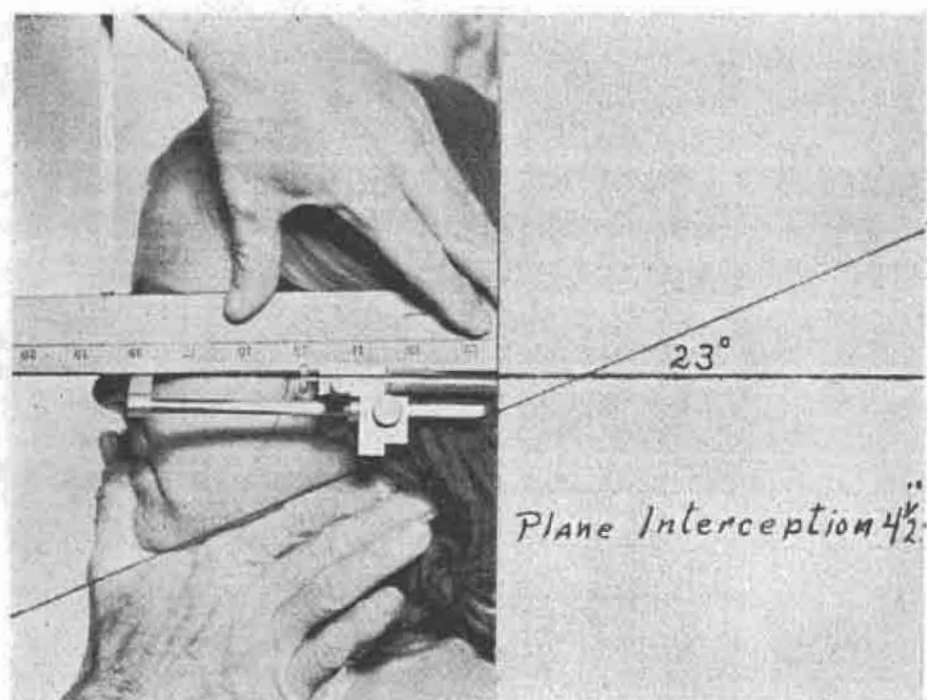


Fig. 22.—Frankfort-mandibular plane angle is $4\frac{1}{2}$ inches posterior to tragon.

If the Frankfort-mandibular plane angle lies from $3\frac{1}{2}$ to 10 inches posterior to tragon, the growth pattern is normal, or at least favorable, and prognosis is good. This does not mean that extracting of teeth is not indicated. The $\pm 5^\circ$ formula applies to these cases. Prognosis increases from good, when the Frankfort-mandibular plane angle lies 4 inches posterior to tragon, to excellent when it lies 8 or more inches from that point (Fig. 22).

When the Frankfort-mandibular plane angle lies from $1\frac{1}{2}$ to $3\frac{1}{2}$ inches posterior to tragon, the growth pattern has not been so favorable. Prognosis decreases from good, when the Frankfort-mandibular plane angle lies $3\frac{1}{2}$ inches posterior to tragon, to poor when that angle lies at 2 inches. More and more extracting will be necessary in this group. The $\pm 5^\circ$ formula will apply to those cases nearest the $3\frac{1}{2}$ inch extreme and the mandibular incisors will approach the -5° extreme of the + or -5° formula, but the formula will not apply to

those cases nearest the $1\frac{1}{2}$ inch extreme. It becomes quite apparent, because of the angular variation of the lower border of the mandible, that it would be much better and more simple to relate the inclinations of the mandibular incisors to either the Frankfort or Bolton plane rather than the lower border of the mandible. The reason is that the $\pm 5^\circ$ formula can be applied to the lower border only when the face pattern is normal or nearly so.

When the Frankfort-mandibular plane angle falls closer than $1\frac{1}{2}$ inches posterior to tragon, the growth pattern is so abnormal that there is little the orthodontist can do for these sled-runners and Class III's.

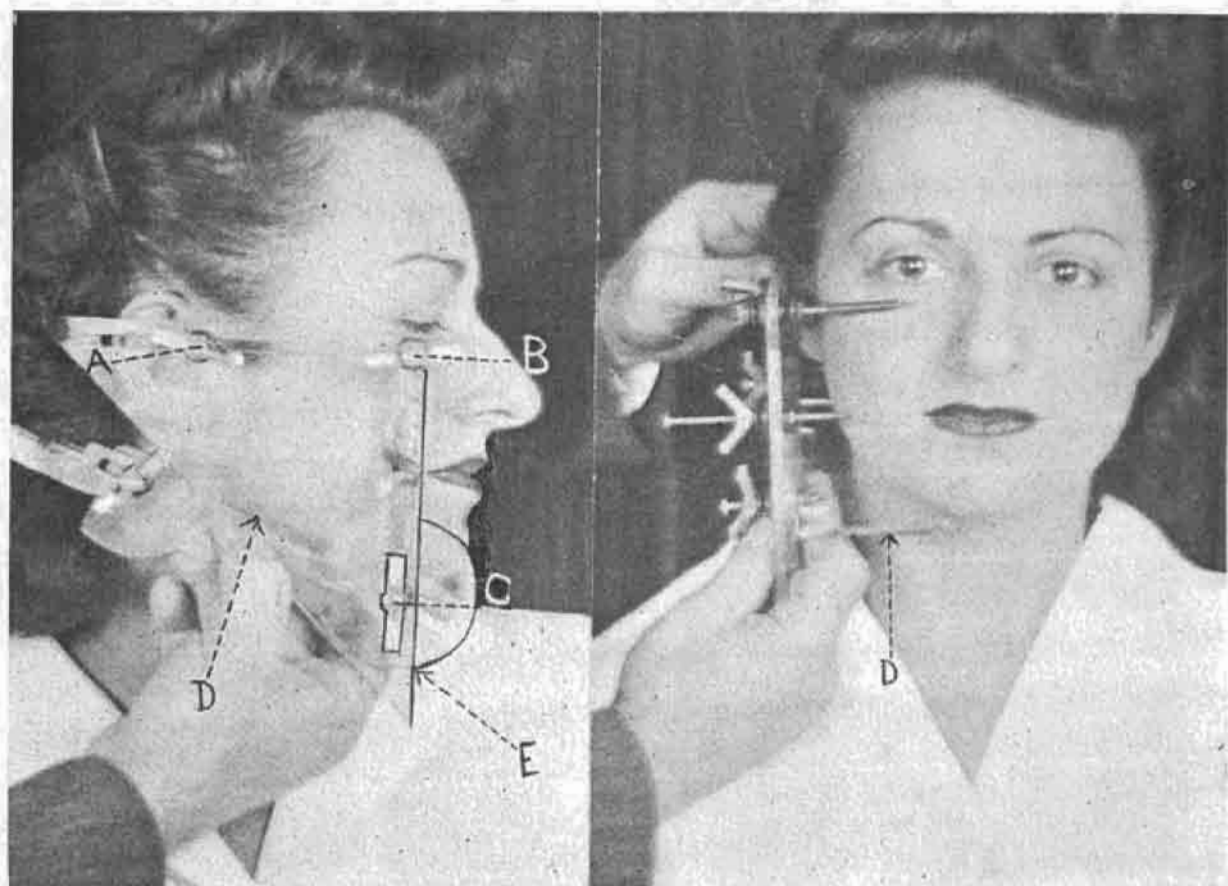


Fig. 23.—The Salzmann Maxillator. Left A, Tragon point screw; B, orbital point screw; C, screw in vertical slot used to adjust the Mandibular Base Piece D, against the base of the mandible. Photograph on right shows front view of maxillator applied to face of patient. D indicates Mandibular Base Piece against base of mandible. (Courtesy Dr. J. A. Salzmann.)

If Salzmann's Maxillator²¹ is used, the Frankfort-mandibular base angle is obtained by direct measurement on the head of the patient and read on the right-hand side protractor on the mandibular base piece. This gives the reading without resorting to the foregoing method or to profile roentgenograms or photographs.

To obtain the Frankfort-mandibular plane angle with the Salzmann Maxillator, the patient is seated upright with the head on a line with the torso.

Place the Maxillator with screw assemblies A and B (see Fig. 23) at the tragon and orbital points, respectively. Sight along the vertical millimeter scale for the length of the face at the orbital plane. Adjust screw assembly C to this point. Adjust the Mandibular

Base Piece *D* so that it lies flat and is pressed against the lower border of the mandible, while screw assemblies *A* and *B* are maintained at their respective points on the face, indicating the Frankfort plane.

The Frankfort-mandibular plane angle is the angle formed by the Frankfort plane and the plane tangent to the base of the body of the mandible and is shown on the Maxillator on the protractor at the bottom of the circumference of the circle on the right side of the Mandibular Base Piece, *E*, where the latter is crossed by the edge of the vertical 6-inch side of the Maxillator.

The illustrations shown in Figs. 24 to 45 present additional evidence in confirmation of the philosophy and method of procedure set forth in this paper.

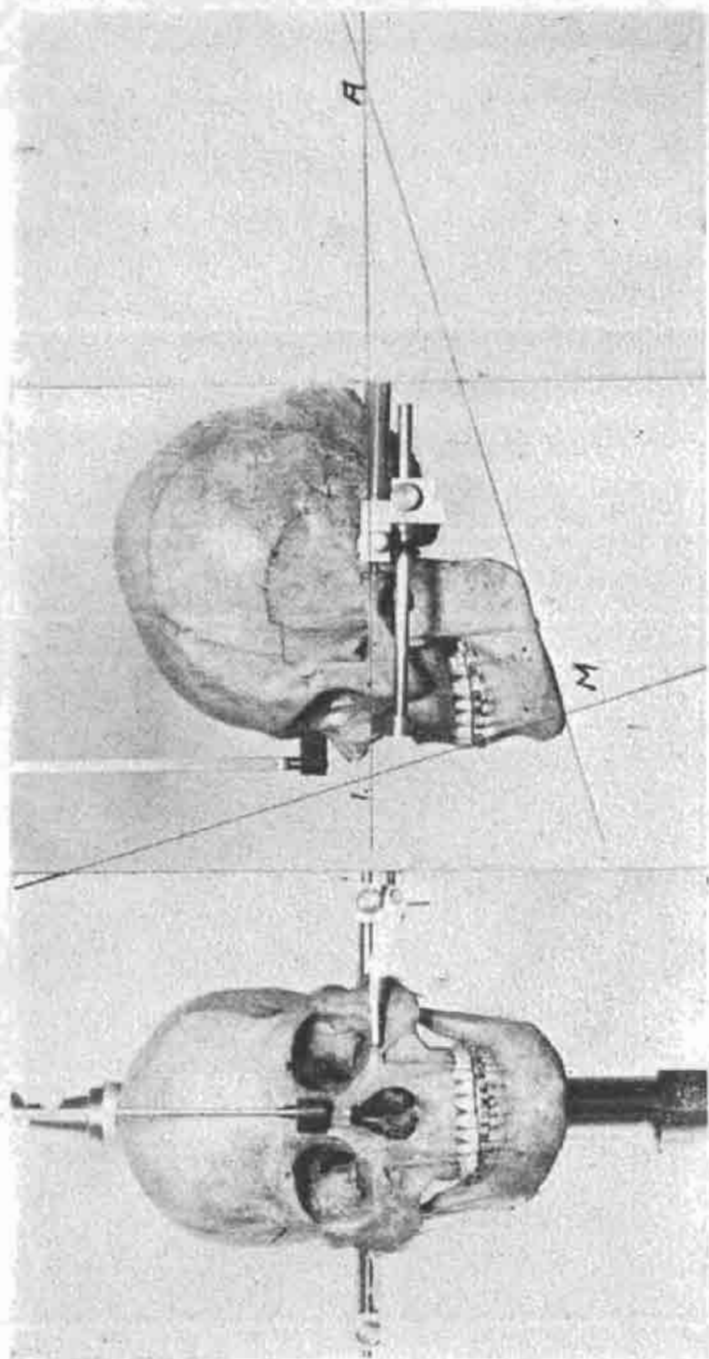


Fig. 24.—A skull of an Arizona Indian with a close approach to normal occlusion. The directional growth of the face is splendid and the Frankfort-mandibular plane angle is 16° . By erecting a perpendicular line from the lower border of the mandible through the long axis of the mandibular central incisor, it will be seen that this line intercepts the Frankfort plane in such a manner that the angle *MJA* is formed. This angle is 73° and I feel that by calling the 73° angle the norm, it would perhaps be easier to relate the inclinations of the mandibular incisors. I believe that all normal face patterns will fall within a minus to plus 7° , 73° being the norm. In other words, the normal range of the inclinations of the mandibular incisors as related to the Frankfort plane is 66° to 80° .

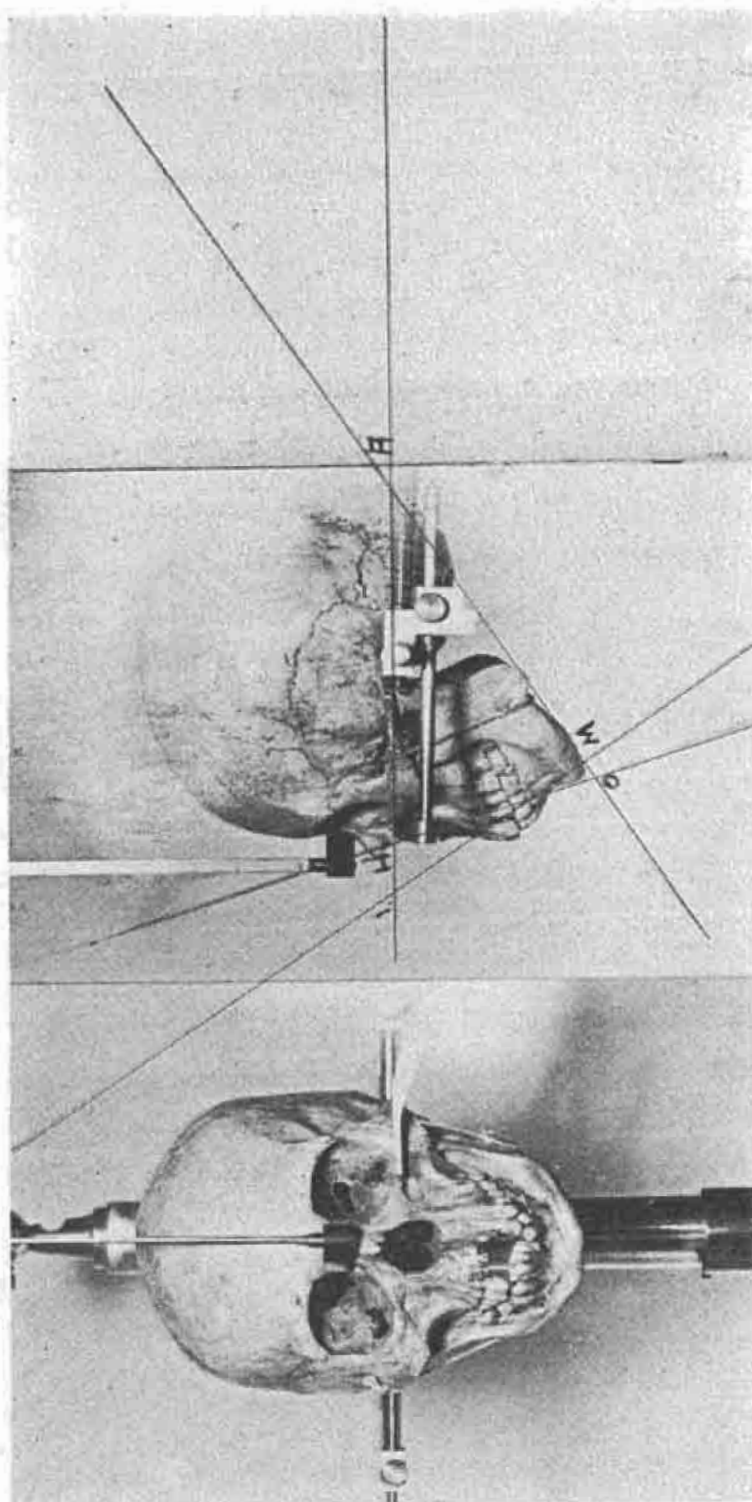


Fig. 25.—This is the skull of an Arizona Indian with a chaotic growth pattern. When a line perpendicular to the lower border of the mandible and passing through the apices of the mandibular incisors is extended upward to intercept the Frankfort plane, the angle $M I A$ formed reads $56\frac{1}{2}^{\circ}$. If the norm is an angle of 73° plus or minus 7° , it becomes obvious that this norm could not be attained for this individual. Construction of an incisor Frankfort angle of 73° is viewed in the angle $O H A$. It becomes clear that it would be a physical impossibility to position the mandibular incisors at $H O$ which is the norm. Therefore, the case is one in which all orthodontic objectives cannot be attained.

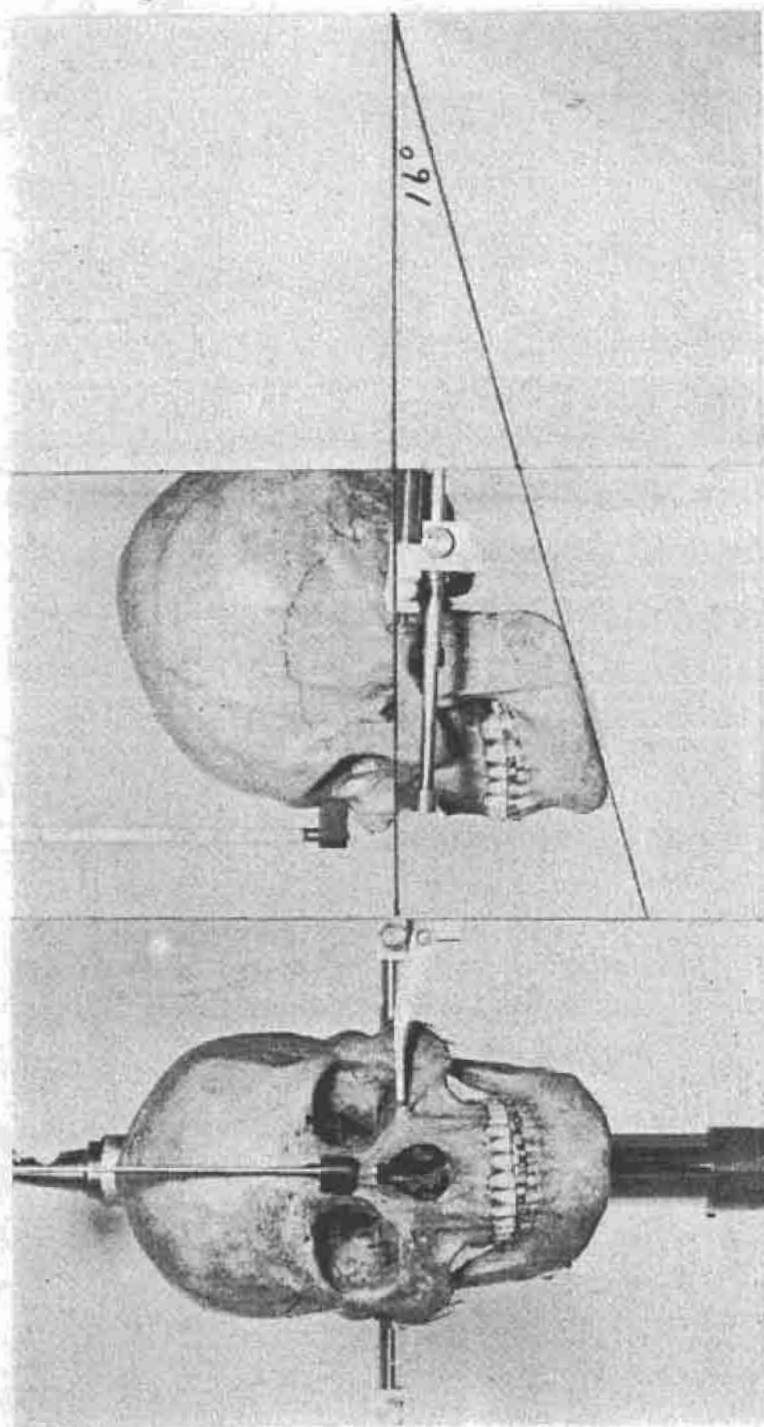


Fig. 26.—An Arizona Indian skull. The denture and growth pattern of the face are both normal. The Frankfort-mandibular plane angle is 16°. Gnathion lies directly below subnasion.

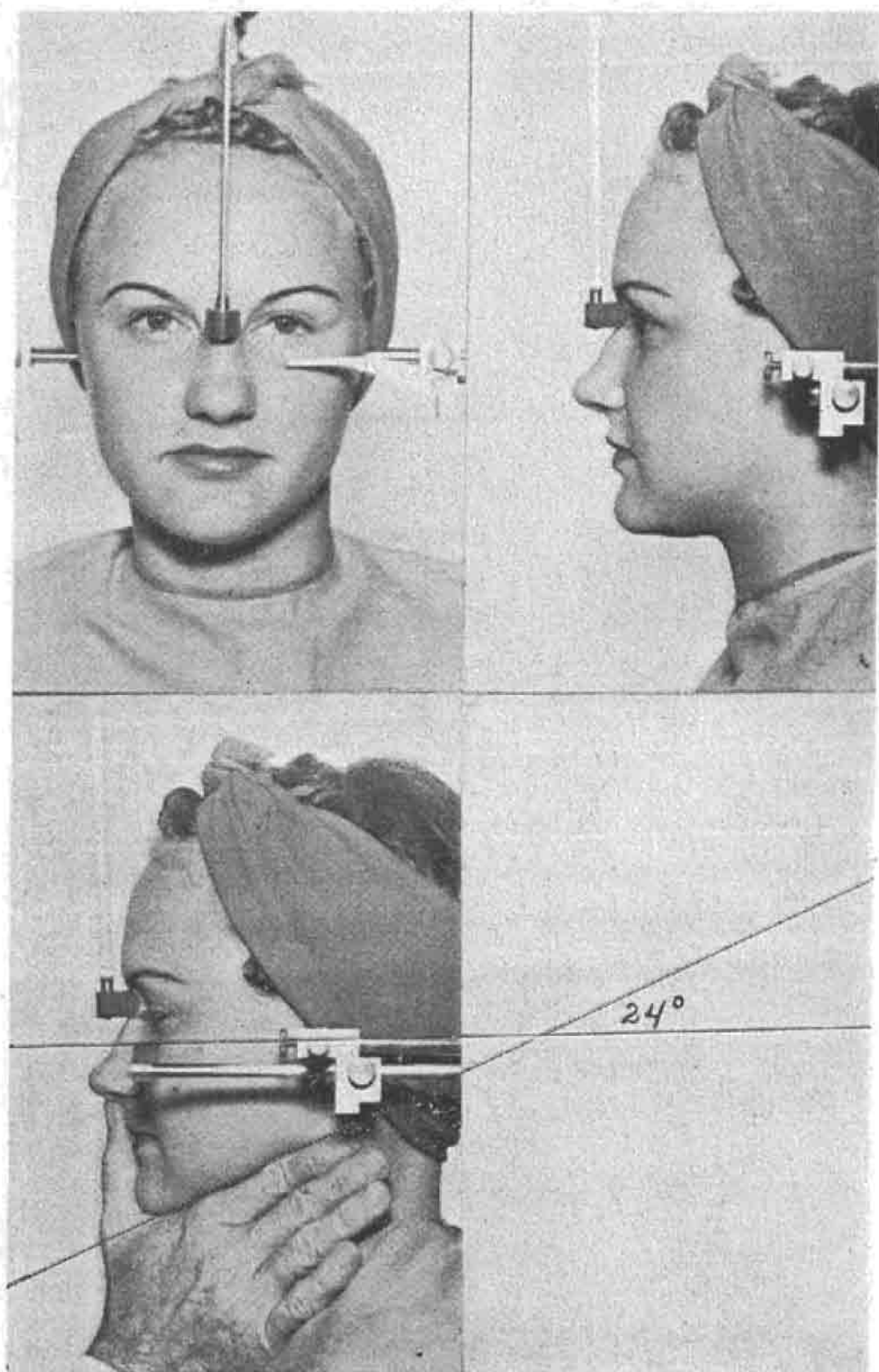


Fig. 27.—A nonorthodontic normal occlusion. The Frankfort-mandibular plane angle is 24° . Note the relationship of gnathion to subnasion.

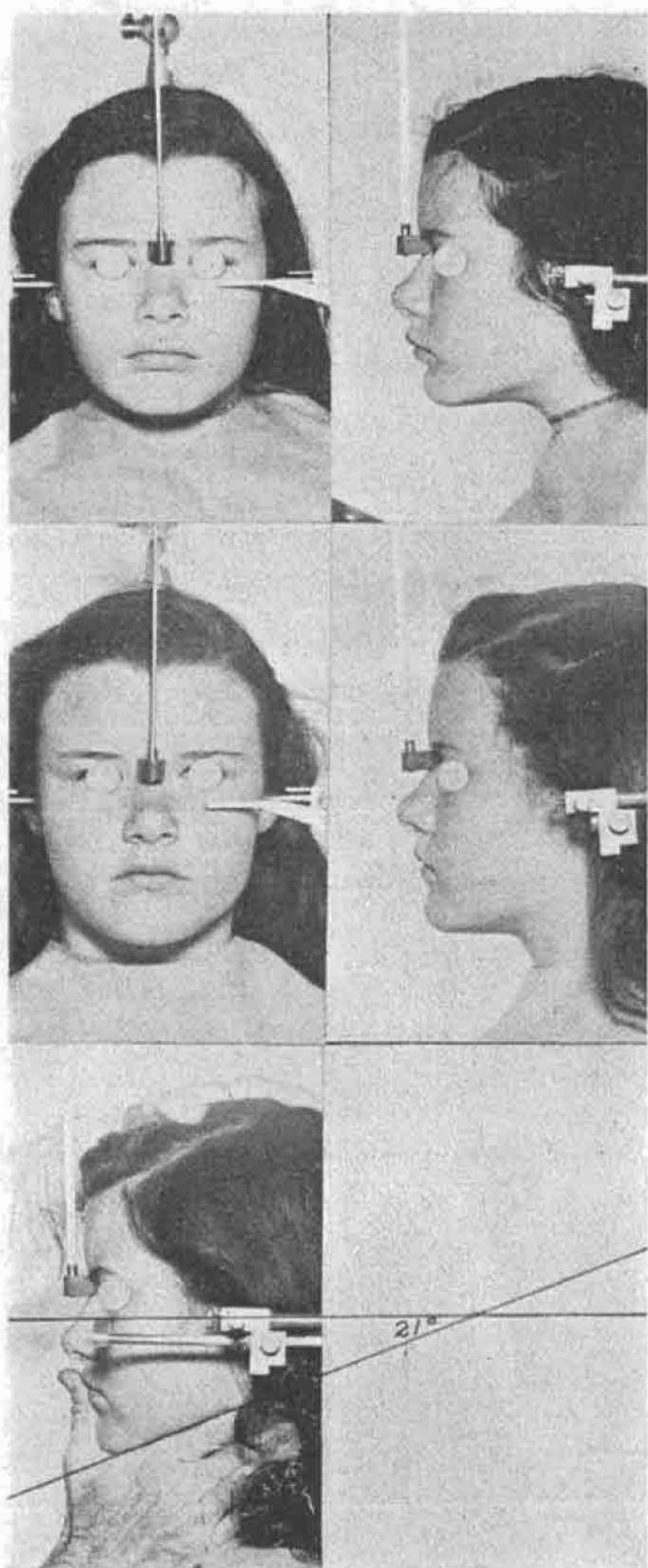


Fig. 28.—A patient presenting a Class II, Division 1 malocclusion in which there is no discrepancy between tooth pattern and basal bone. The Frankfort-mandibular plane angle is 21° . Note the location of gnathion as related to subnasion.

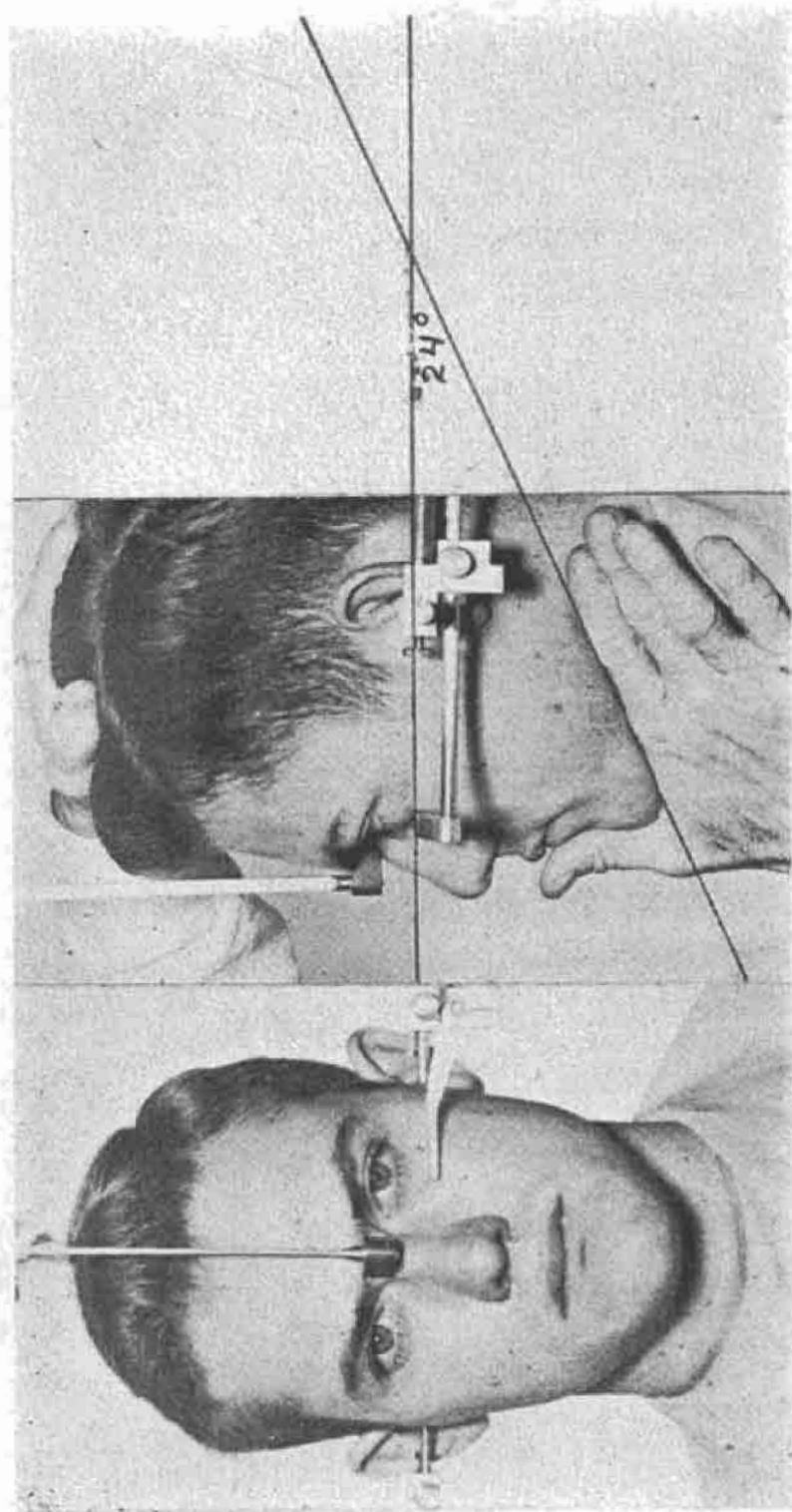


Fig. 29.—Another treated Class I malocclusion in which the Frankfort-mandibular plane angle is within the range of the normal. In this instance it is 24°. Again note the relationship of gnathion to subnasion.

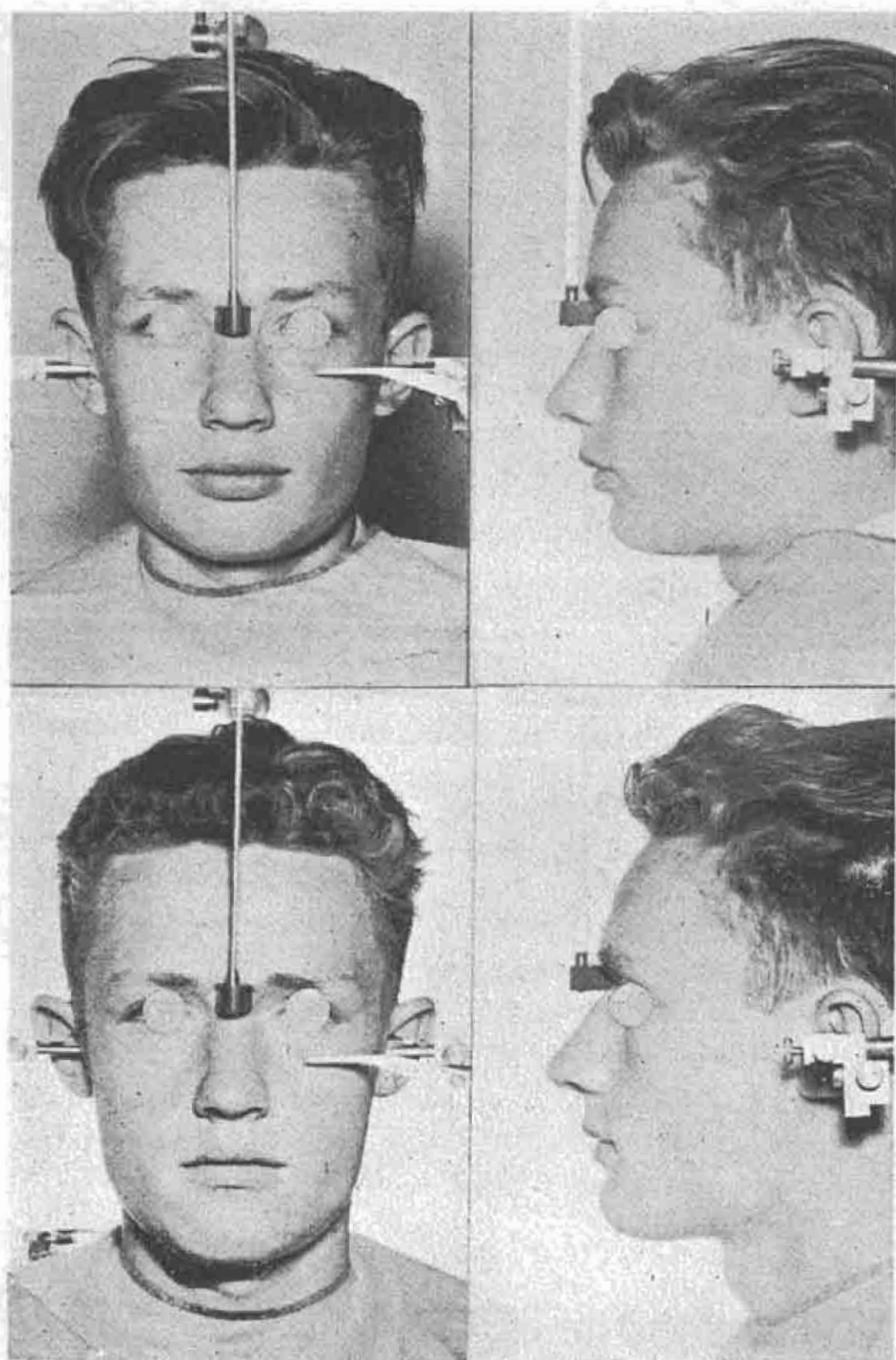


Fig. 30.—Another treated Class II malocclusion with a most favorable Frankfort-mandibular plane angle. A nonextraction case.

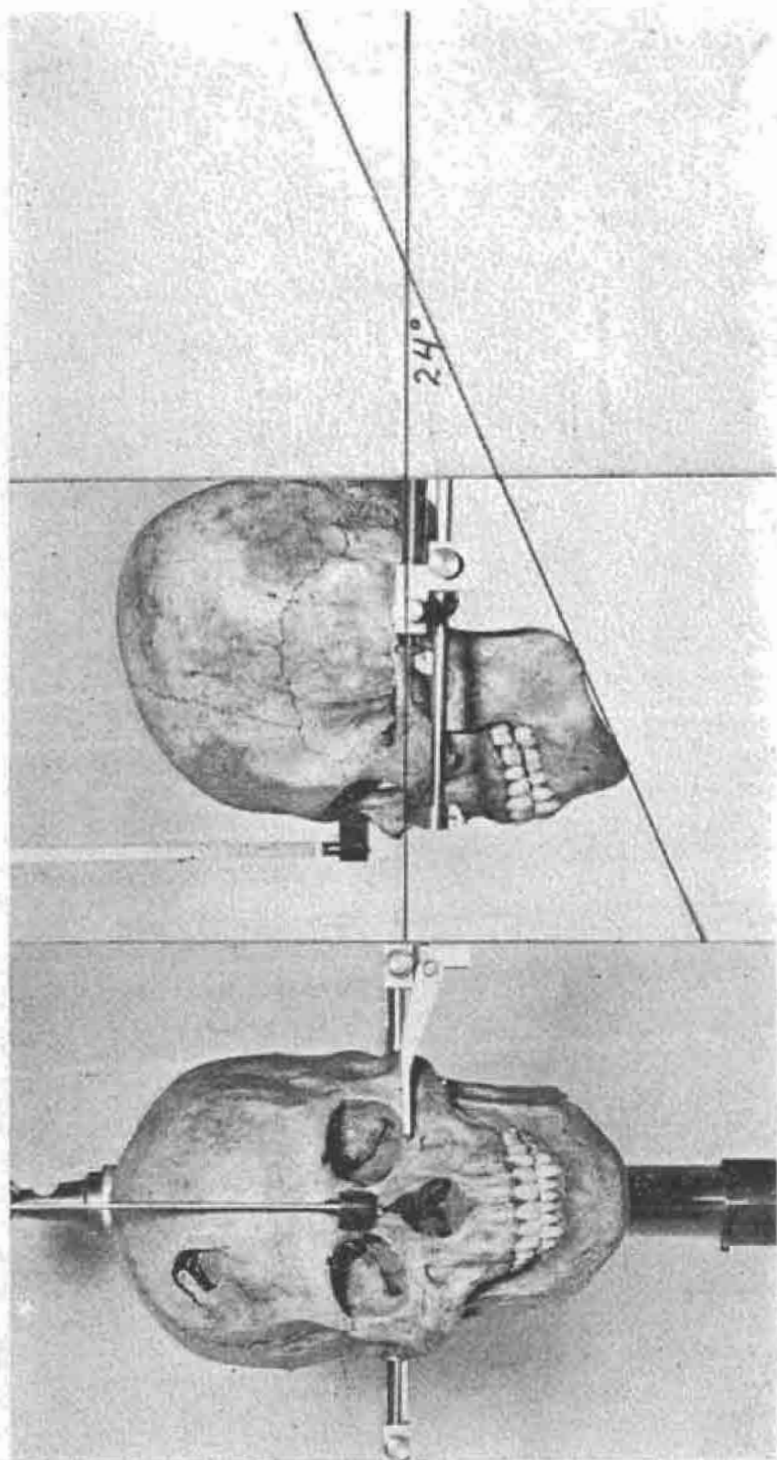


Fig. 31.—The skull of an Arizona Indian. The directional growth of the face is very good. The Frankfort-mandibular plane angle is 24° . There seems to have been lack of growth in the body of the mandible, although the rami are well developed. This is the type of case that orthodontists must learn to recognize and treat correctly by removing all four first premolars to correct the discrepancy between tooth pattern and medullary bone. This must be done if facial esthetics are ever to simulate the normal.

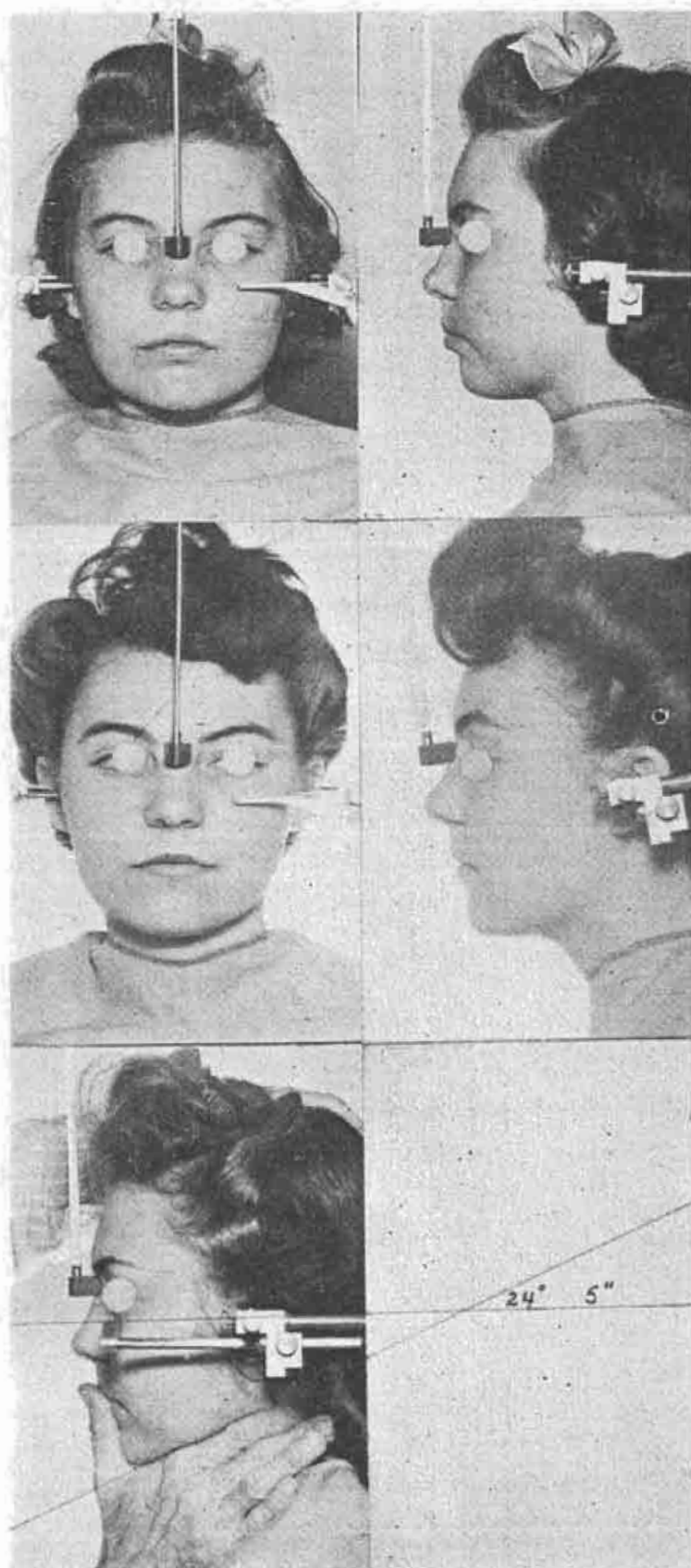

Fig. 32.—A treated case with an osseous configuration similar to that of the skull in Fig. 31. The Frankfort-mandibular plane angle is 24° and the discrepancy between tooth pattern and medullary bone has been corrected with the results viewed in the illustration. Note that gnathion is not as far forward as related to subnasion as was true in the previous illustration.

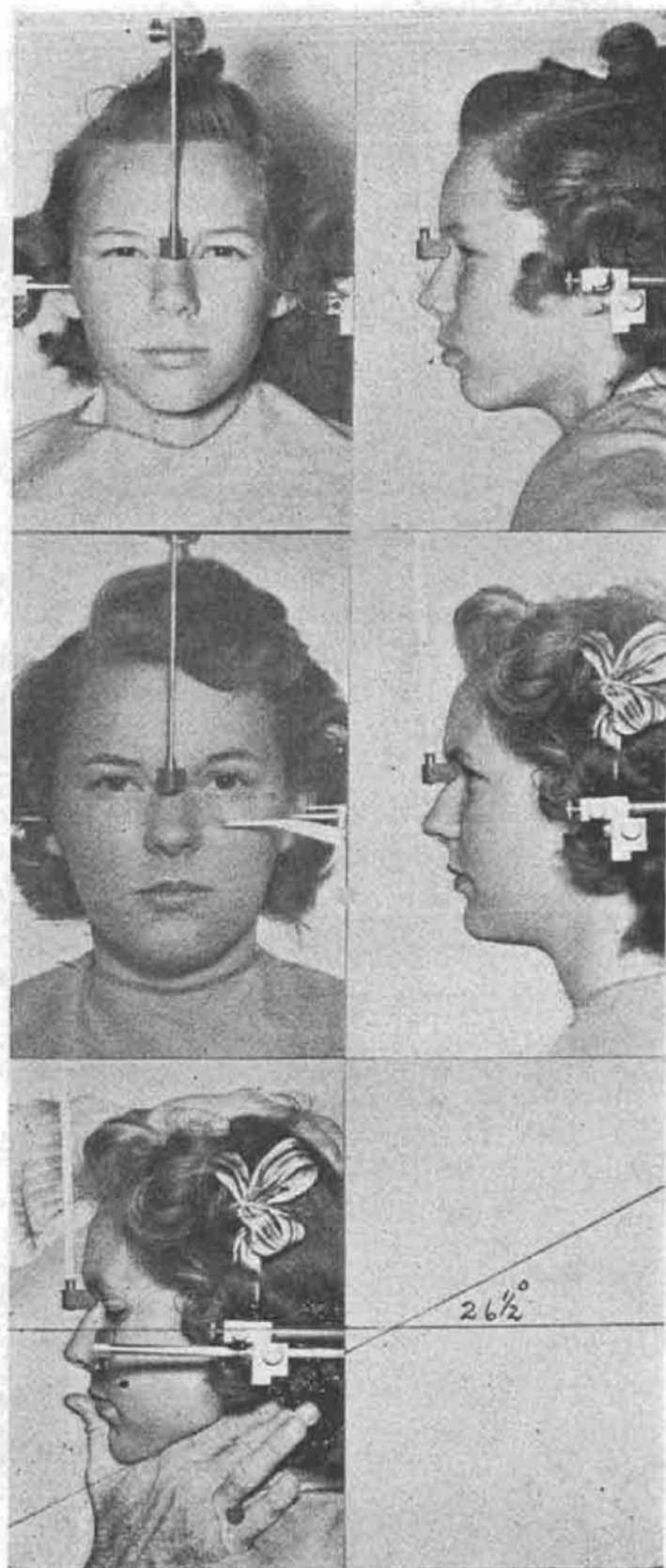

Fig. 33.—Another treated malocclusion in which the Frankfort-mandibular plane angle is $26\frac{1}{2}^{\circ}$, hence prognosis is most favorable. An extraction case.

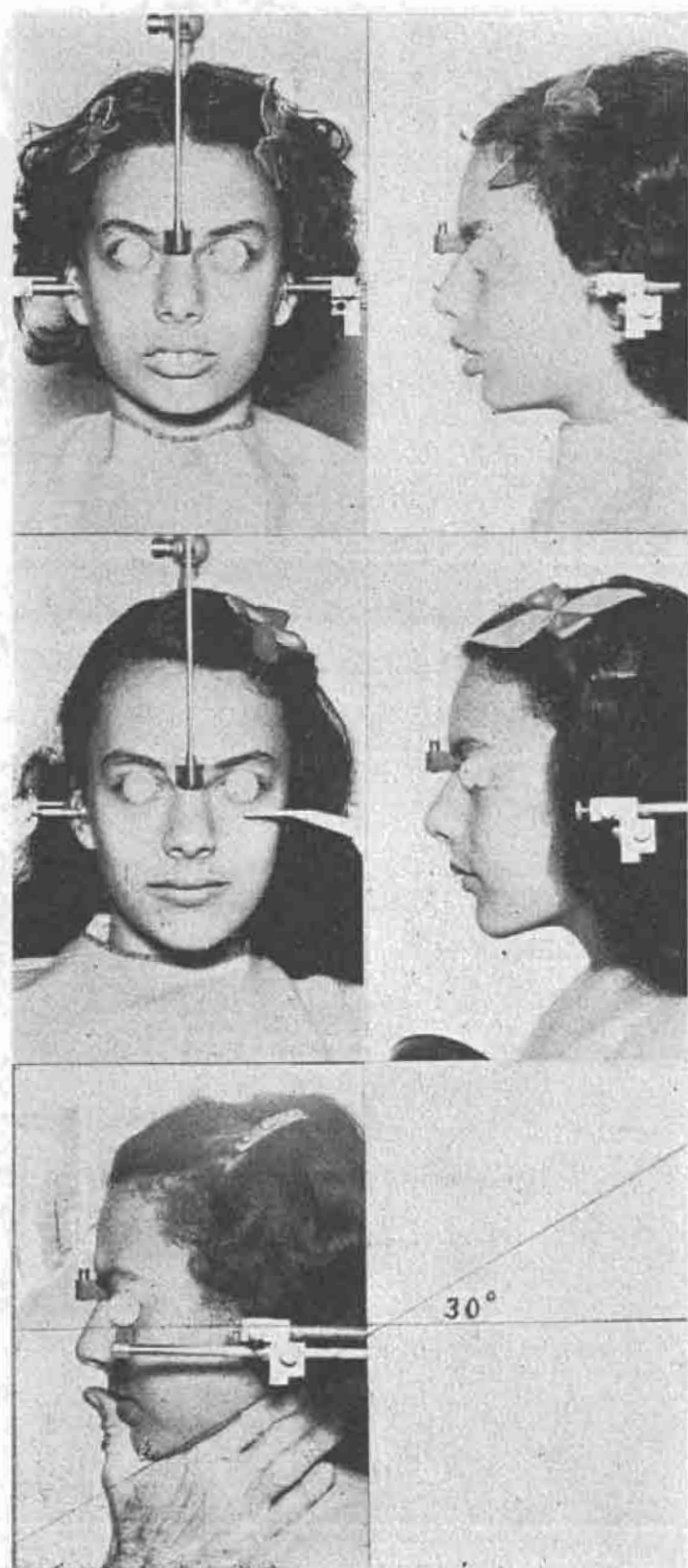


Fig. 34.—Here the patient presents a face pattern not quite as favorable as the previous patient. The Frankfort-mandibular plane angle is 30° , and while the lower part of the face is a bit diminutive, favorable proportions have been maintained. An extraction case. Note that gnathion lies farther distal in its relation to subnasion.

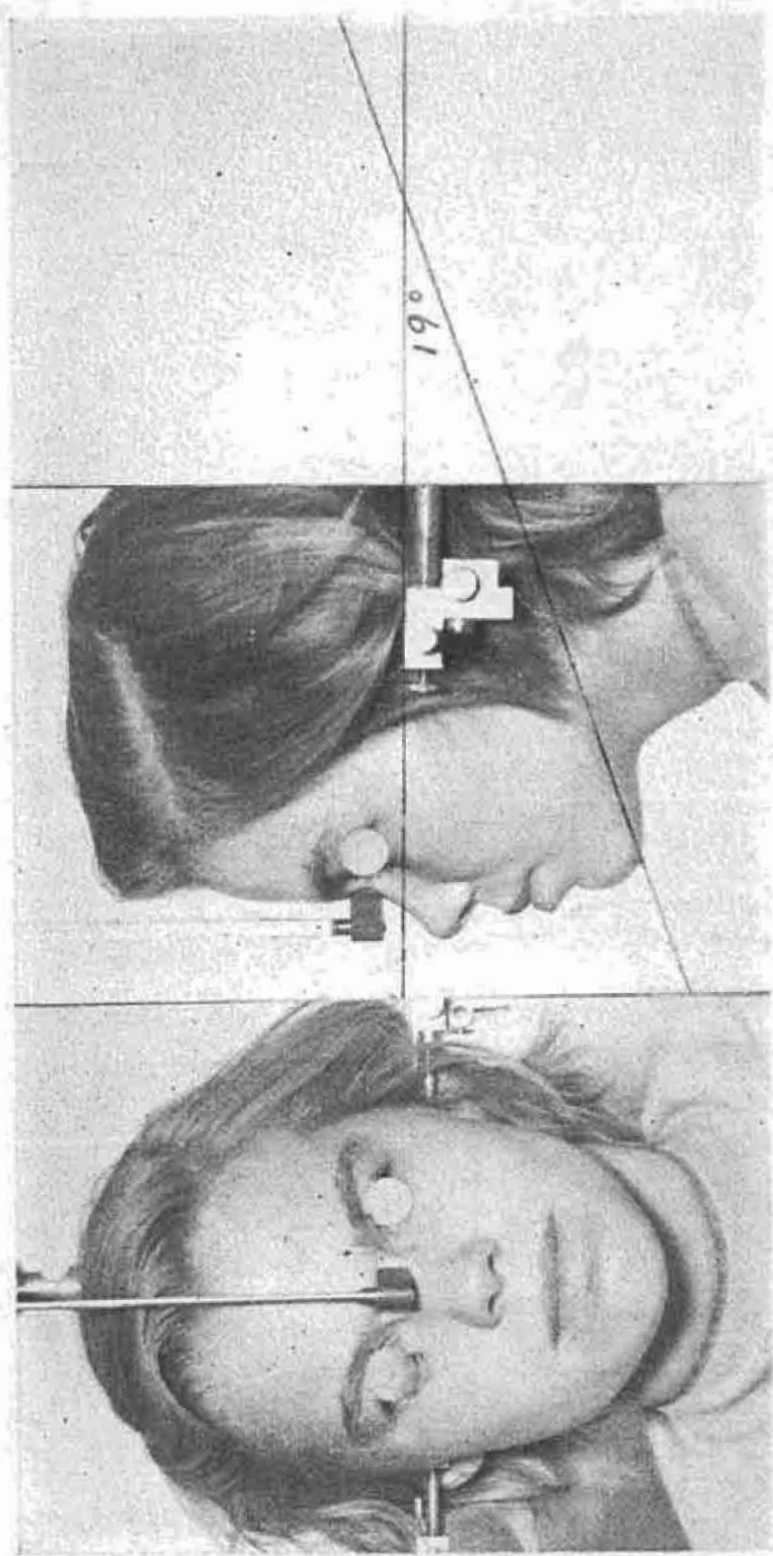


Fig. 35.—An orthodontic tragedy. Here the patient presents a Frankfort-mandibular plane angle of approximately 19° . Gnathion lies directly under subnasion. The directional growth is beautiful and yet because some orthodontist refused to recognize the existing discrepancy between tooth pattern and basal bone, this result was made possible.

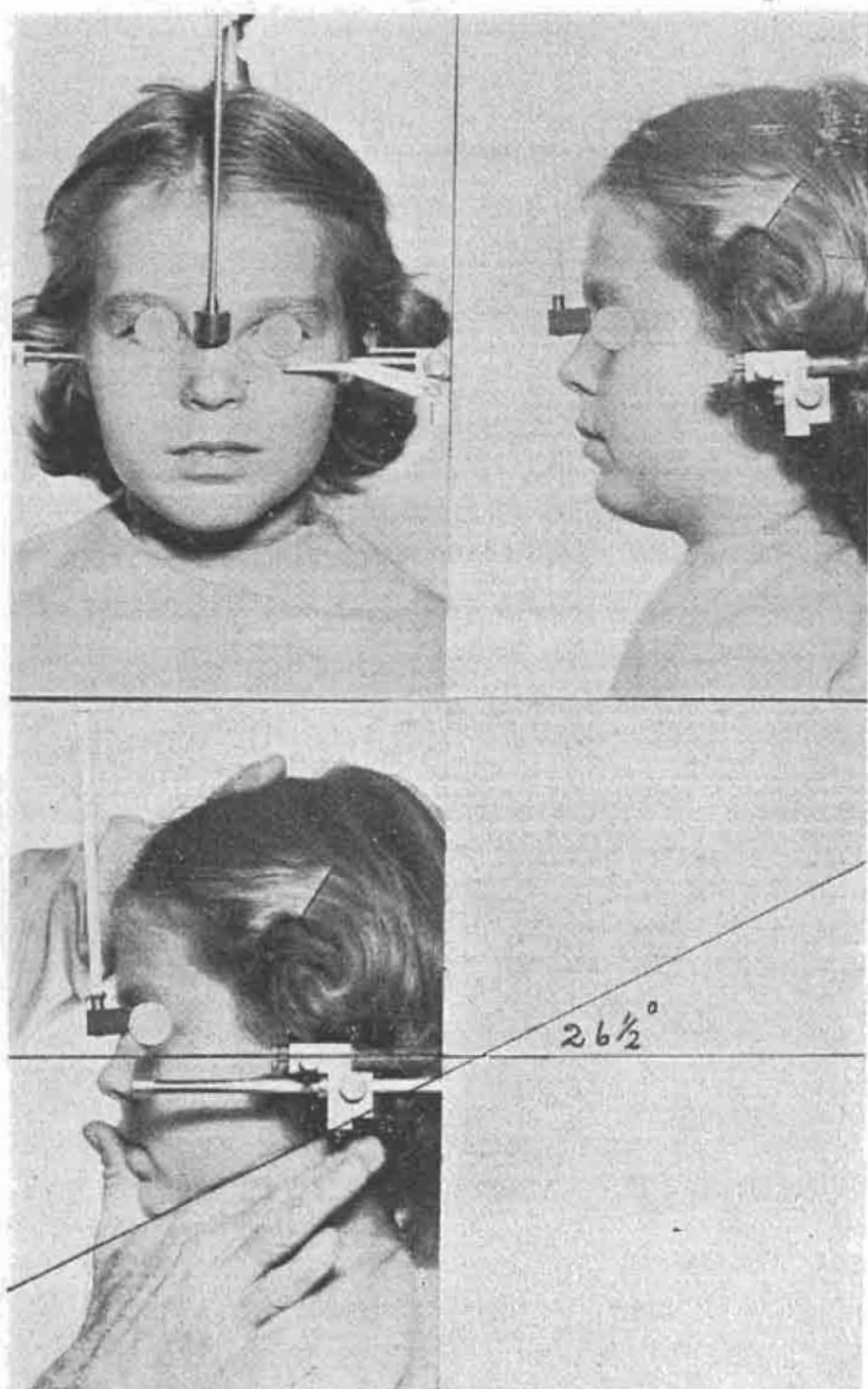


Fig. 36.—A young nonorthodontic patient who has a most favorable directional growth pattern, the Frankfort-mandibular plane angle being $26\frac{1}{2}^{\circ}$. It is quite obvious to all who have made a study of faces that there is a discrepancy between tooth pattern and basal bone which will require the removal of all four first premolars at a later date if the orthodontic objectives that should be attained are actually attained.

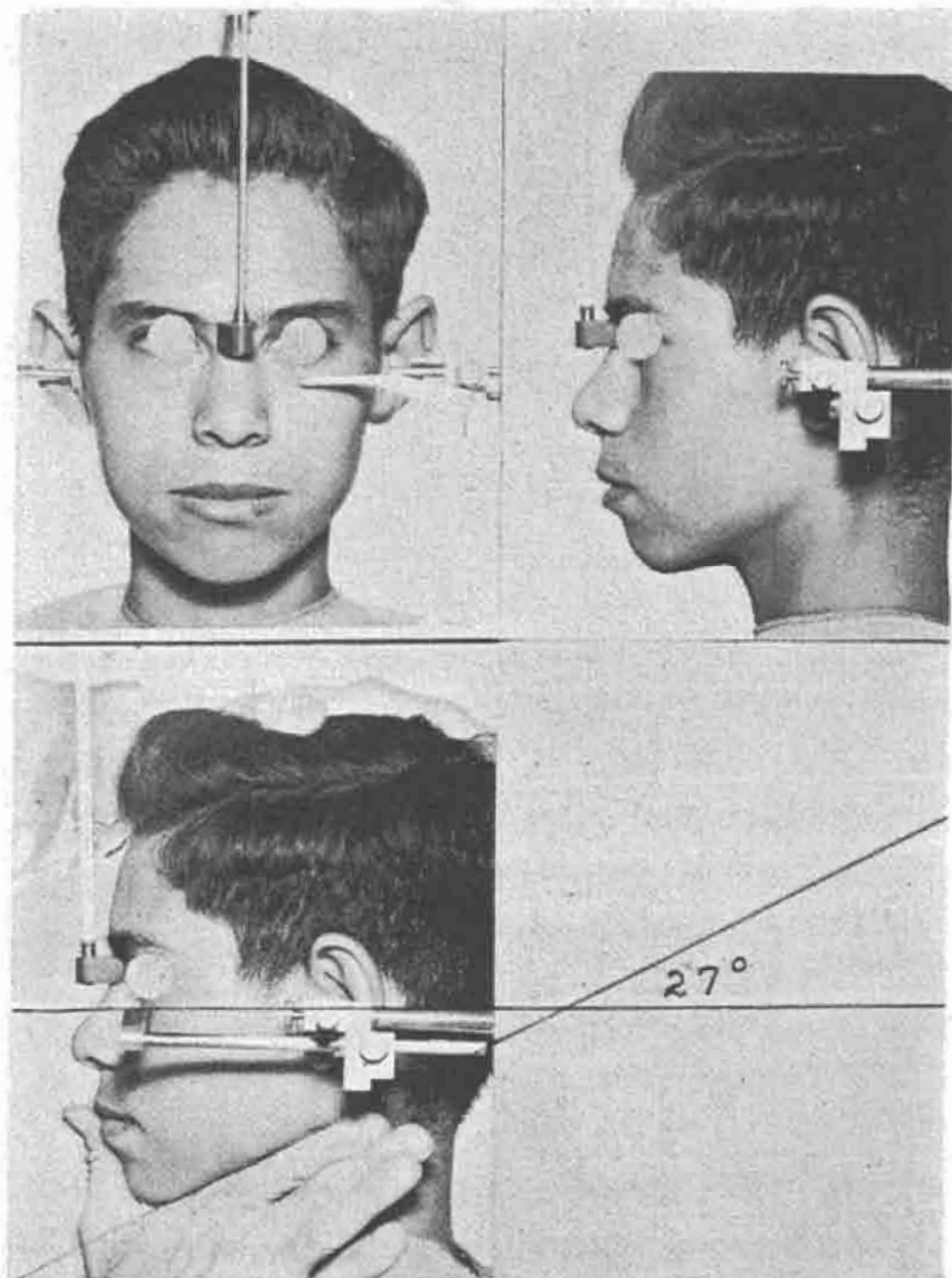


Fig. 37.—A typical nonorthodontic bimaxillary protrusion. The Frankfort-mandibular plane angle is 27° , and the directional growth of the face is fair. Some would call this a normal occlusion, but I cannot agree with them, even though the cuspal relations are normal. An obvious case in which all four first premolars must be removed if all orthodontic objectives are to be attained.

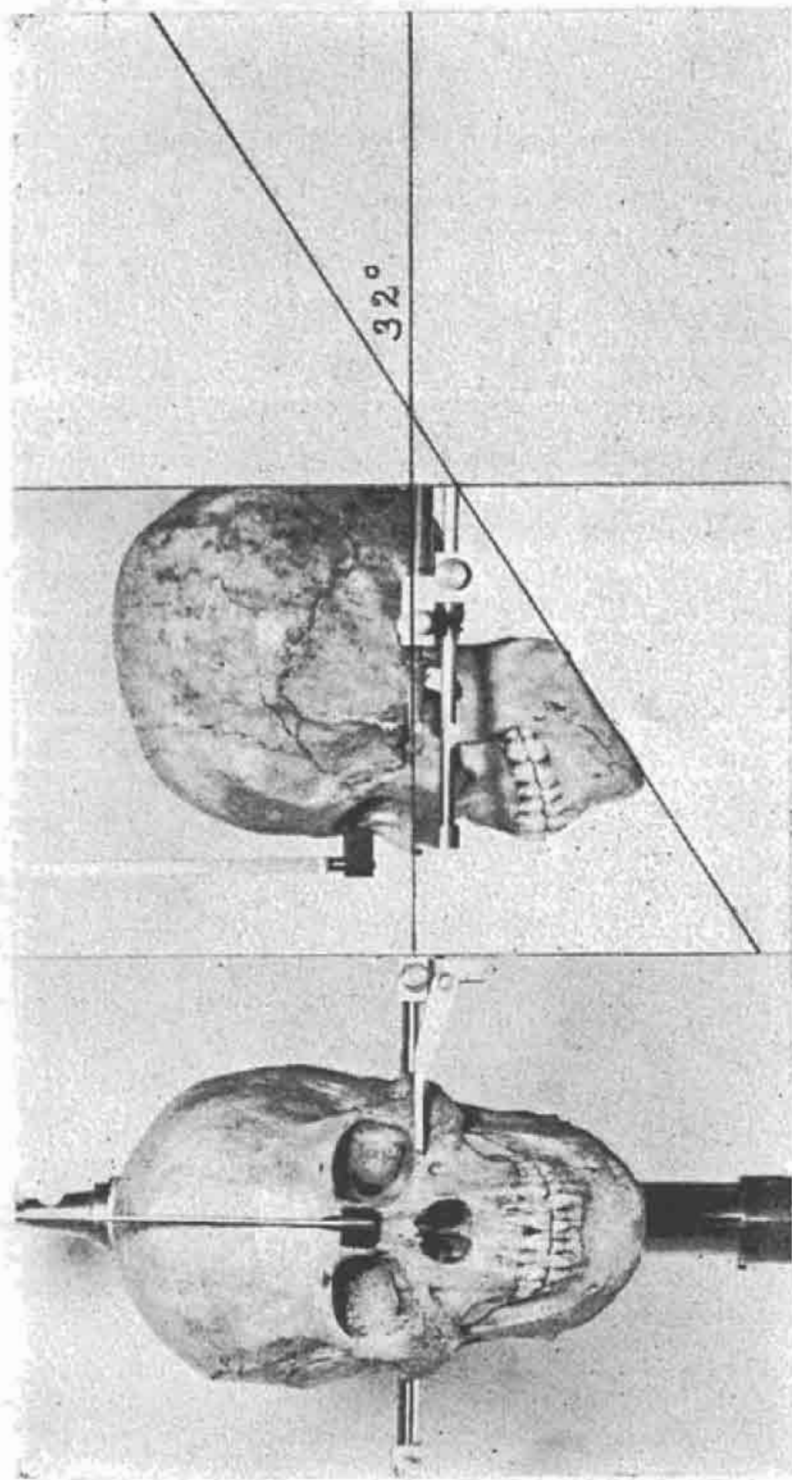


Fig. 38.—A skull of an Arizona Indian. The growth vector is too much downward and not enough forward. The Frankfort-mandibular plane angle is 32° . Note that gnathion lies a bit posterior to subnasion. Virtually all cases presenting the above symptoms will require the removal of all four first premolars. When the Frankfort-mandibular plane angle ranges from 28° to 32° , or to the degree seen in this skull, the 45° formula will not apply. These cases can be greatly benefited by orthodontic treatment, but they can by no means be considered normal because there has been a fault in growth that has altered the normal growth pattern.

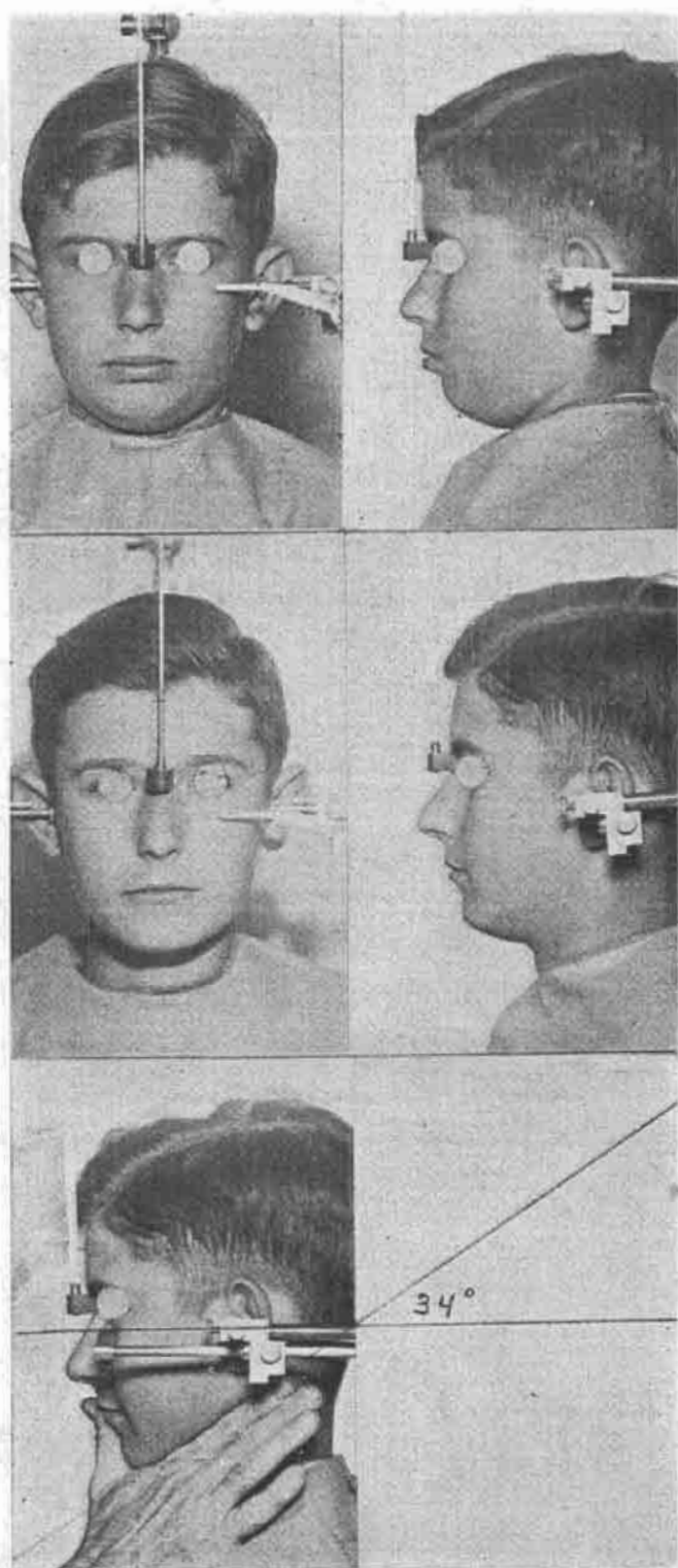


Fig. 39.—A treated case in which the Frankfort-mandibular plane angle is 34° . The face is greatly improved and so is the occlusion. An extraction case.

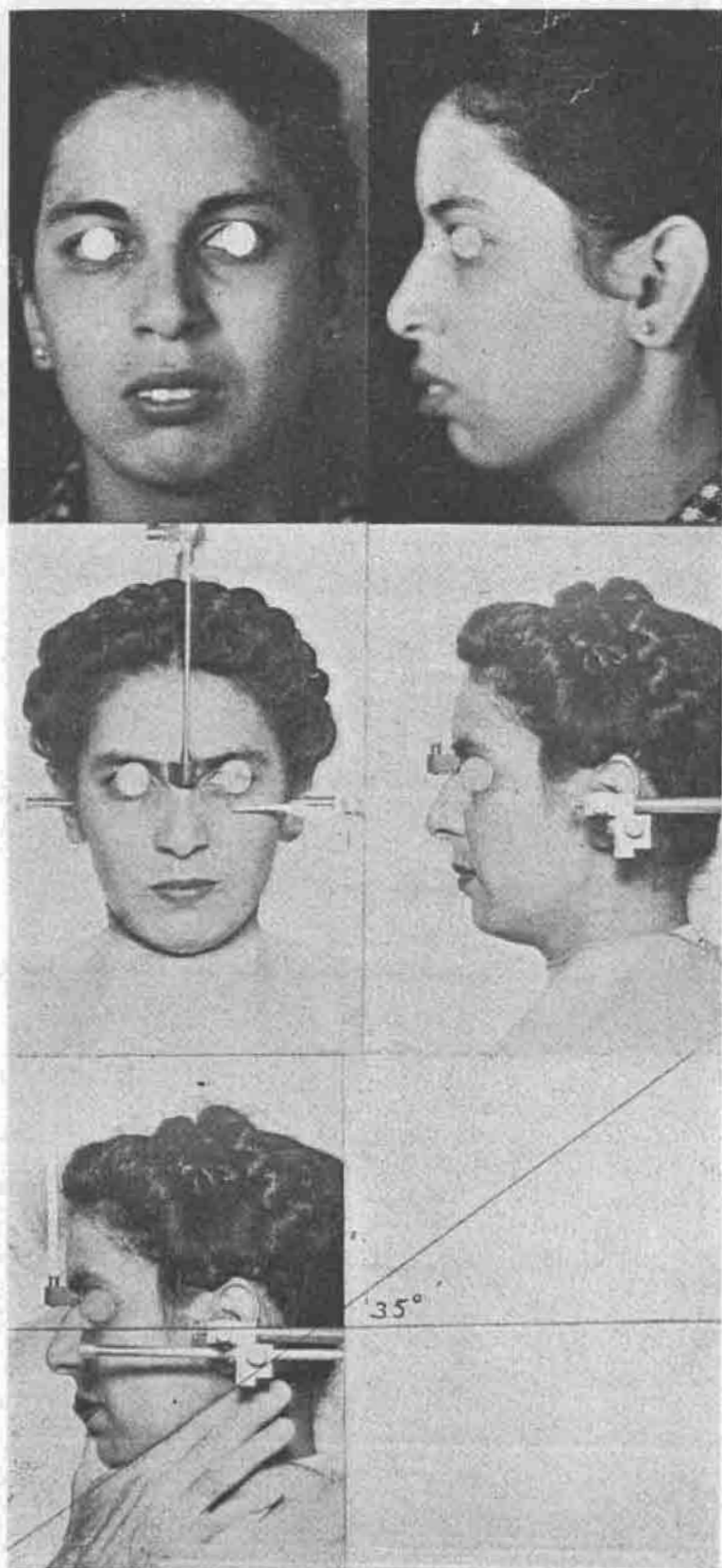


Fig. 40.—A severe Class II malocclusion complicated by a discrepancy between tooth pattern and basal bone. The case was treated ten years ago. The Frankfort-mandibular plane angle is 35° , and while the face is by no means normal, it is a gratifying improvement.

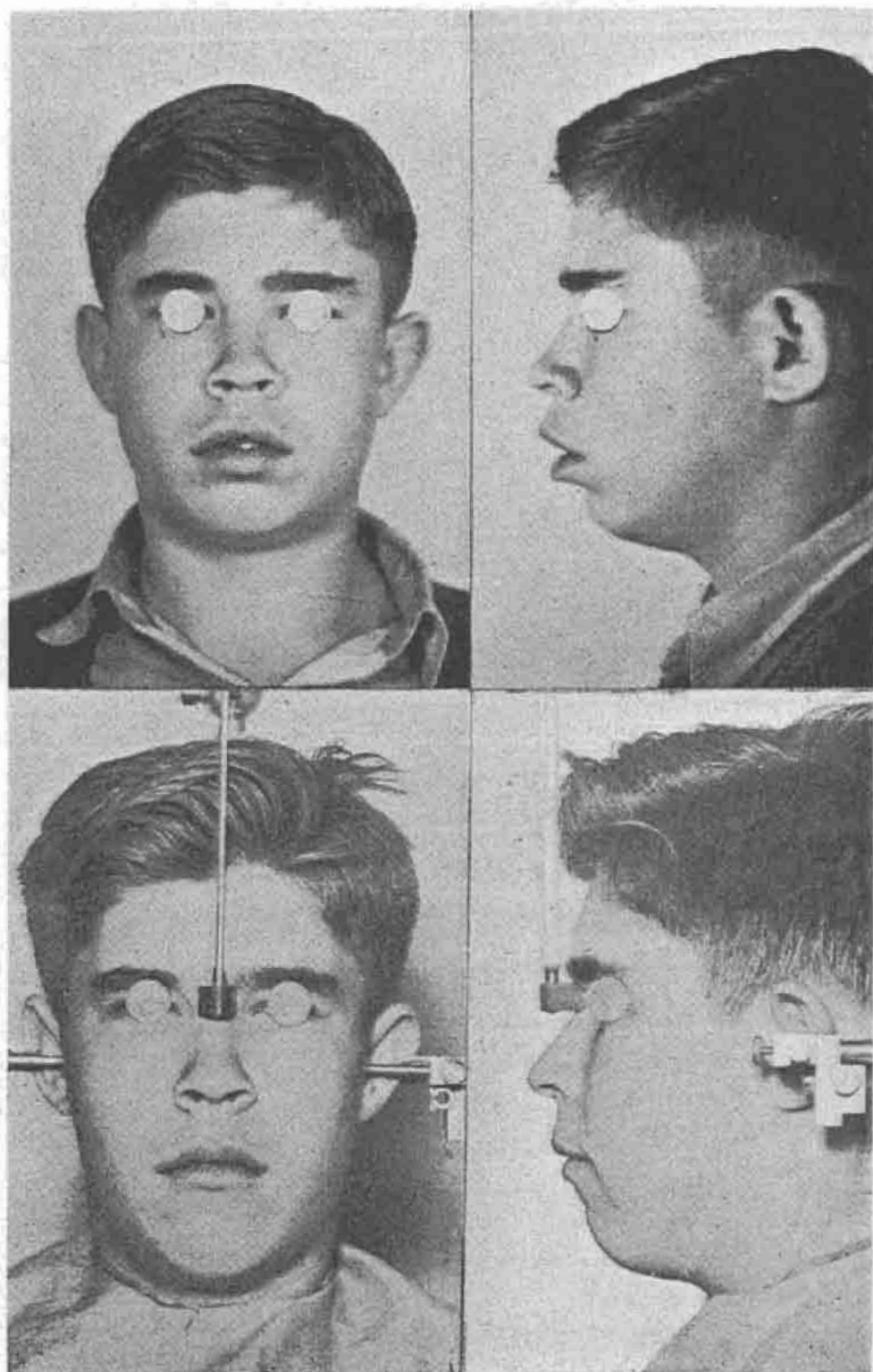


Fig. 41.—Here the Frankfort-mandibular plane angle must be a bit beyond 35° . All four first premolars were extracted and facial esthetics and occlusion have been greatly improved, although facial esthetics are far from normal.

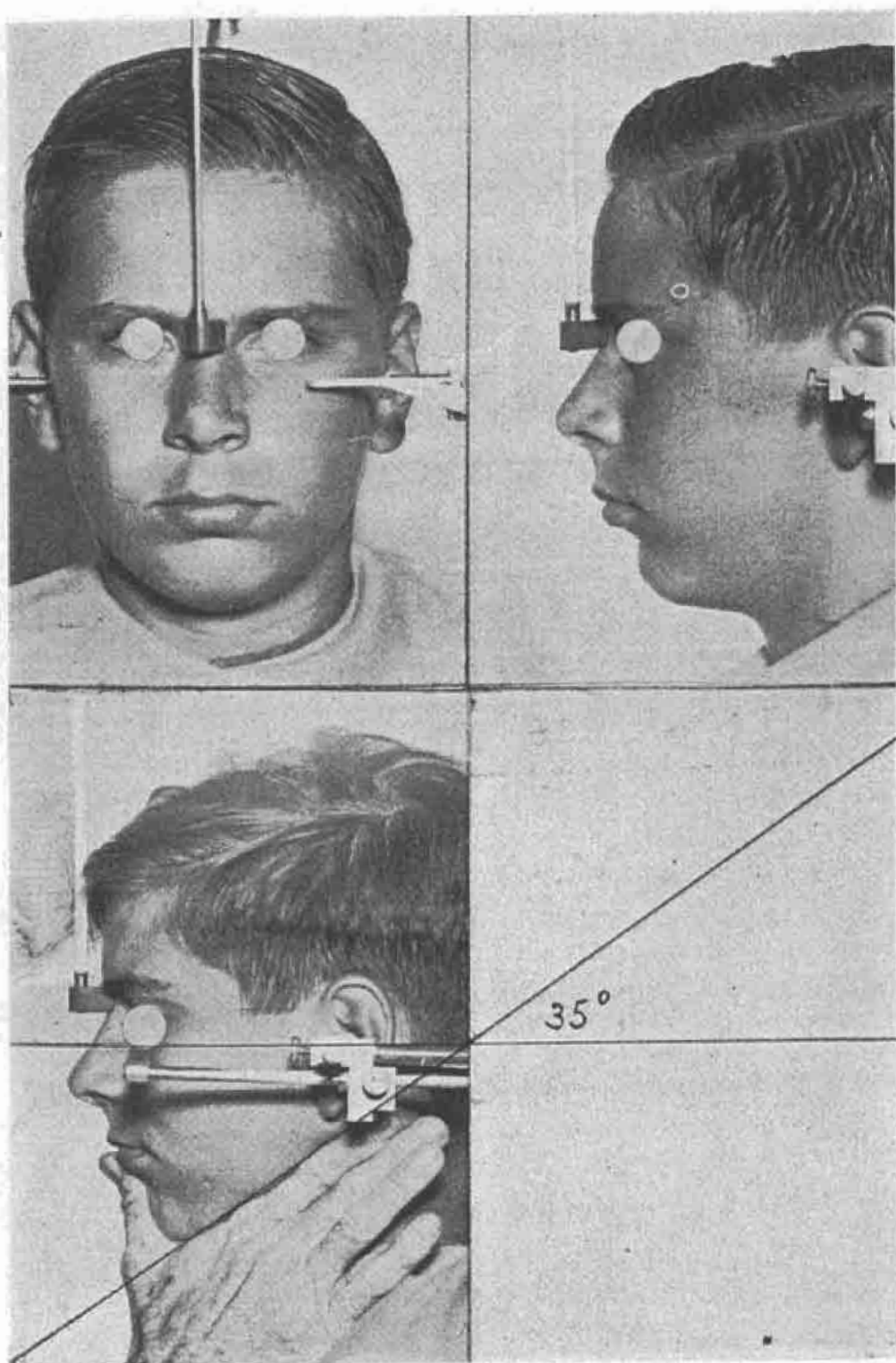


Fig. 42.—This lad presents a Frankfort-mandibular plane angle of 35° . Prognosis is not good so far as facial esthetics are concerned. An extraction case.

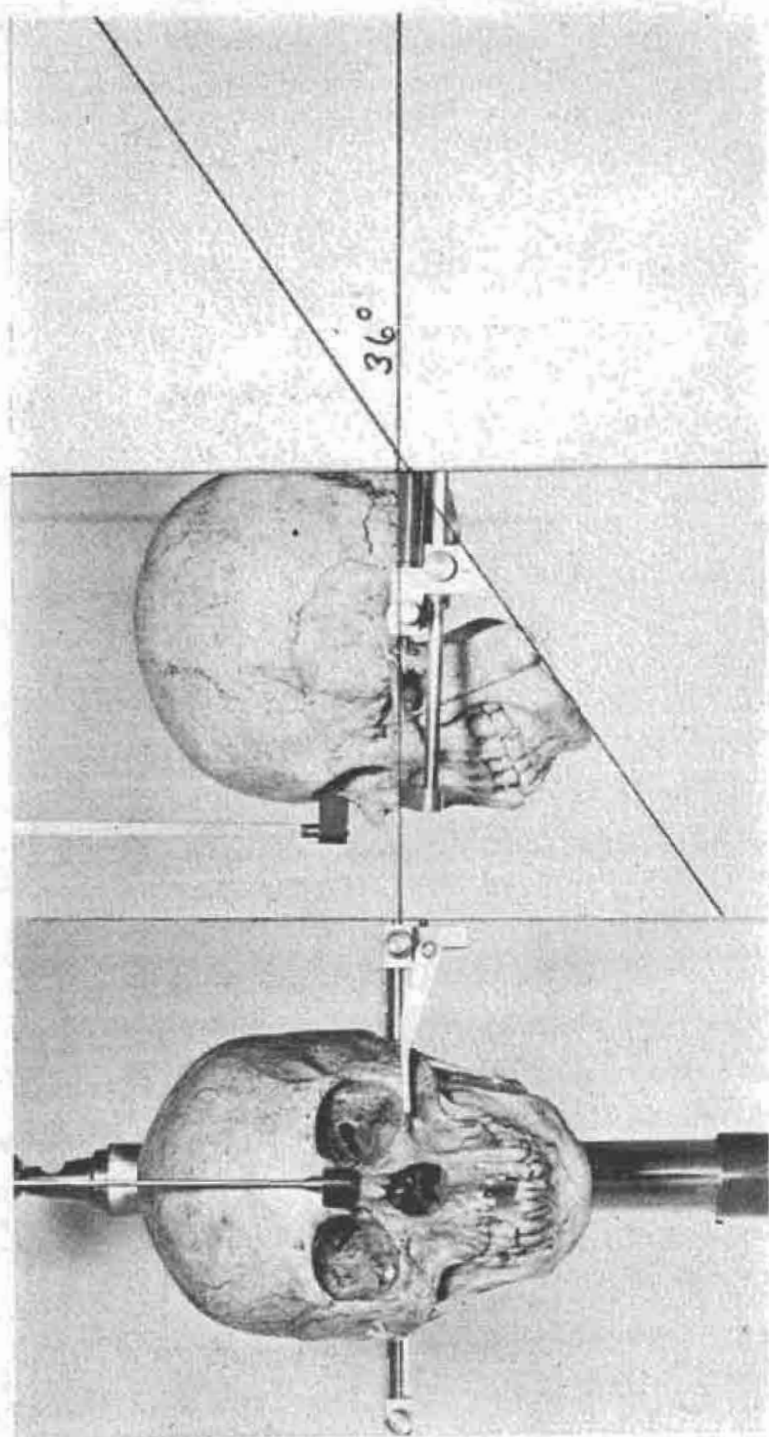


Fig. 43.—The skull of an Arizona Indian. The growth pattern is chaotic. The Frankfort-mandibular plane angle is 36° . The directional growth of the face is bad. Note the position of gnathion as related to subnasion. Extractions in such a case would perhaps be contraindicated in orthodontic treatment.



Fig. 44.—A treated orthodontic case that presents a Frankfort-mandibular plane angle of approximately 39°. A grave error was made in resorting to the extraction of all four first premolars.

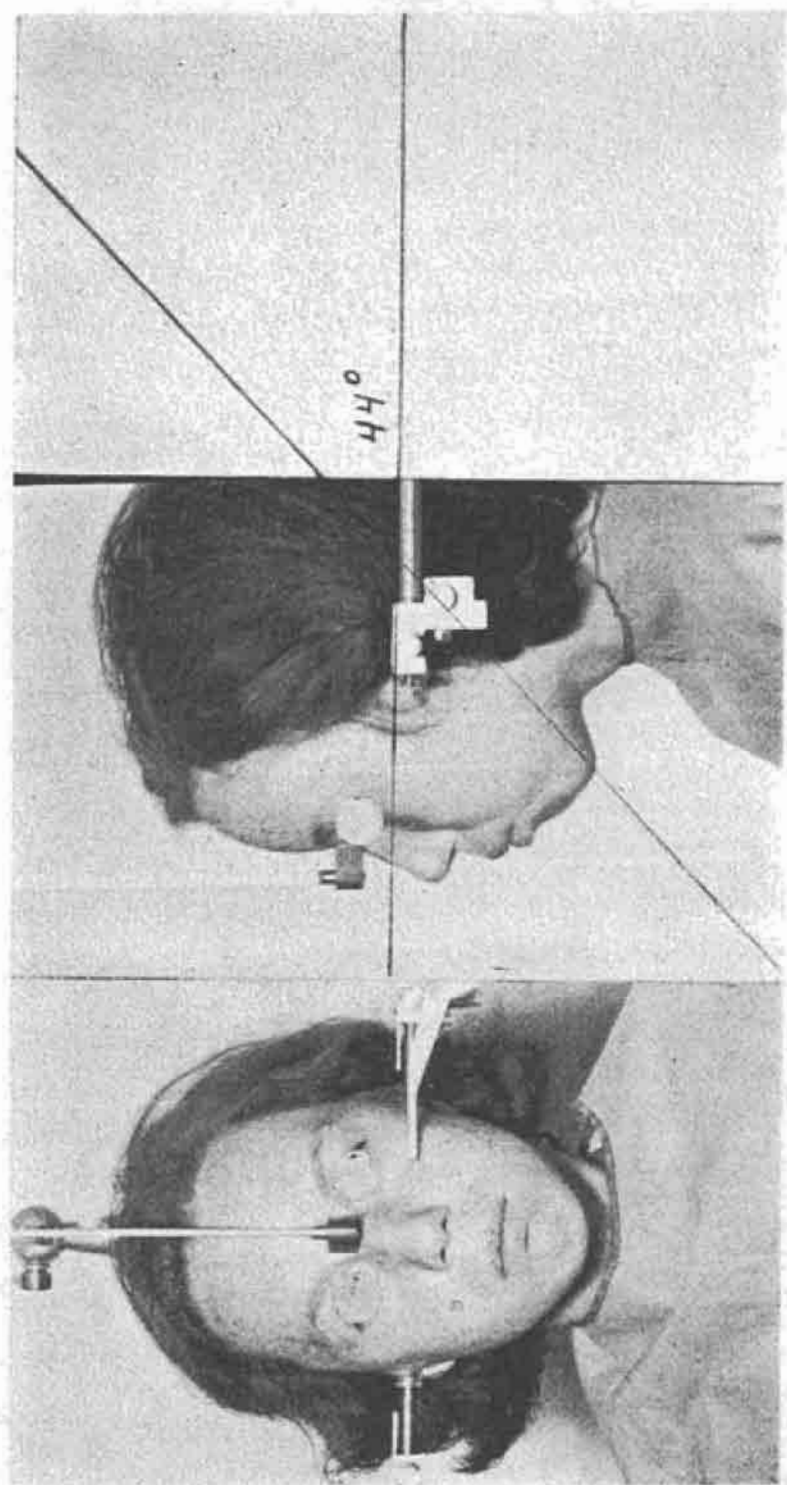


FIG. 45.—A case in which the Frankfort-mandibular plane angle is 44° . The face is chaotic. Extraction would not be indicated. There is little the orthodontist can do for this type of case.

I wish to acknowledge with thanks the assistance of Dr. J. A. Salzmann in the preparation of this paper.

REFERENCES

1. Angle, Edward H.: Malocclusion of the Teeth, ed. 7, 1907, S. S. White Dental Manufacturing Co.
2. Tweed, Charles H.: The Application of the Principles of the Edgewise Arch in the Treatment of Malocclusion. I, II, Angle Orthodontist 11: 5, 12, 1941.
3. Tweed, Charles H.: Indications for the Extraction of Teeth in Orthodontic Procedure, AM. J. ORTHODONTICS AND ORAL SURG. 30: 405, 1944.
4. Broadbent, B. Holly: The Face of the Normal Child, Angle Orthodontist 7: 183, 1937.
5. Brodie, Allan G.: On the Growth Pattern of the Human Head From the Third Month to the Eighth Year of Life, Am. J. Anat. 68: 209, 1941.
6. Margolis, Herbert I.: A Plastic and Graphic Technique for Recording Dental Changes and Facial Growth, AM. J. ORTHODONTICS AND ORAL SURG. 25: 1027, 1939; Standardized X-Ray Cephalographics, Ibid. 26: 725, 1940. See also Salzmann, J. A.: Principles of Orthodontics, Philadelphia, 1943, J. B. Lippincott Co., pp. 96-97.
7. Margolis, Herbert I.: The Axial Inclination of the Mandibular Incisors, AM. J. ORTHODONTICS AND ORAL SURG. 29: 571, 1943.
8. Margolis, Herbert I.: Unpublished material. (See Discussion.)
9. Salzmann, J. A.: The Rationale of Extraction as an Adjunct to Orthodontic Mechanotherapy and the Sequelae of Extraction in the Absence of Orthodontic Guidance, AM. J. ORTHODONTICS AND ORAL SURG. 31: 181, 1945; Principles of Orthodontics, Philadelphia, 1943, J. B. Lippincott Co., pp. 320-385.
10. Schour, I., and Massler, Maury: The Growth Pattern of Human Teeth. Part 1, J. Am. Dent. A. 27: 1778, 1940; Part 2, J. Am. Dent. A. 27: 1918, 1940.
11. Schour, I.: Rate of Growth of Alveolar Bone Measured by Alizarine Injections, J. Dent. Research 15: 329, 1936; The Tooth as an Index of the Constitutional Pattern of the Child, Proc. Third Bien. Meeting, Society Res. Child Dev. Nat. Res. Council, 109-110, 1939.
12. Salzmann, J. A.: Principles of Orthodontics, Philadelphia, 1943, J. B. Lippincott Co., pp. 26-28.
13. Broadbent, B. Holly: The Orthodontic Value of Studies in Facial Growth, Physical and Mental Adolescent Growth, Proc. of Conf. on Adol. Cleveland, 37-39, 1930; Ontogenetic Development of Occlusion, In: Development of Occlusion, Philadelphia, 1941, University of Pennsylvania Press, pp. 31-48.
14. Gregory, William K.: The Evolution of Dental Occlusion From Fish to Man, In: Development of Occlusion, Philadelphia, 1941, University of Pennsylvania Press, pp. 1-30.
15. Gregory, William K.: The Origin and Evolution of the Human Dentition, Baltimore, 1922, Williams & Wilkins Co.
16. Brodie, Allan G.: Some Recent Observations on the Growth of the Mandible, Angle Orthodontist 10: 63, 1940.
17. Schour, I., Hoffman, M. M., Sarnat, B. G., and Engel, M. B.: Vital Staining of Growing Bones and Teeth With Alizarine Red S, J. Dent. Research 20: 411, 1941; Brash, James C.: The Growth of the Jaws, Normal and Abnormal in Health and Disease, London, 1924, The Dental Board of the United Kingdom.
18. Brodie, Allan G.: On the Growth of the Jaws and the Eruption of the Teeth, Angle Orthodontist 12: 102, 1942.
19. Brodie, Allan G.: Some Recent Observations on the Growth of the Face and Their Implications to the Orthodontist, AM. J. ORTHODONTICS AND ORAL SURG. 26: 741, 1940.
20. Broadbent, B. Holly: Ontogenic Development of Occlusion, Angle Orthodontist 11: 223, 1941.
21. Salzmann, J. A.: The Maxillator: A New Instrument for Measuring the Frankfort-Mandibular Base Angle, the Incisor-Mandibular Base Angle, and Other Component Parts of the Face and Jaws, AM. J. ORTHODONTICS AND ORAL SURG. 31: 608, 1945.